

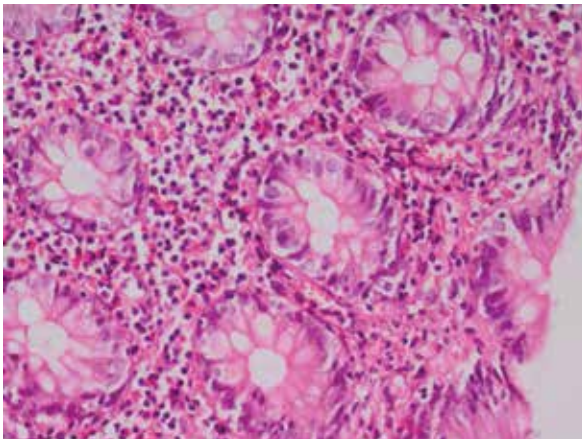


## Eosinophilic colitis presenting with lower gastrointestinal bleeding: An uncommon entity with a rare presentation

To the Editor,

We read with interest the article by Park et al. (1) on eosinophilic colitis (EC) for which symptoms improved by antidepressants and anxiolytics. We present an infrequent case of EC complicated with severe lower gastrointestinal bleeding (LGIB) where the patient was treated with prednisone.

A 54-year-old woman was admitted with complaints of rectal bleeding and severe abdominal pain. She had no other comorbid diseases. Laboratory findings were as follows: serum hemoglobin, 9.7 g/dL; white cell count, 14.000/L with 10% eosinophils (eosinophil count, 1400/L); platelet count, 297.000/L; and other blood cell counts and biochemical tests were within normal limits. She neither had any allergic diseases nor did she use any antibiotics. No unusual findings were observed on physical examination except for diffuse abdominal tenderness. The colonoscopic features were nonspecific, including erythema and oedema. Multiple biopsies were obtained from each segment of the colon. On histopathological examination, the depth of eosino-



**Figure 1.** Eosinophilic colitis histology (>20 eosinophils/high-powered file).

philic infiltration through the colonic layers varied (>20 eosinophils/high-powered file) (Figure 1). Treatment with 40-mg/d prednisone was initiated. Two weeks after the treatment, rectal bleeding and abdominal pain resolved. The patient was discharged from the hospital, and she had no symptoms at the 2-month follow-up.

Eosinophilic colitis is not only a rare clinical manifestation but also a seldom cause of LGIB (2,3). The main clinical presentations are bloody diarrhea and abdominal pain, but it usually represents nonspecific nature of EC. Severe cases may develop severe abdominal pain and distension, malabsorption, intestinal obstruction, severe bloody diarrhea, and even gastrointestinal hemorrhage (4).

As noted by Park et al., there is no consensus on a specific therapy for EC (1,3). Corticosteroids and aminosalicylates are the mainstay for initial management. Therefore, we used steroids unlike Park et al. (1), and the patient's symptoms resolved.

Treatment of EC varies but almost always responds to steroid therapy. On the other hand, the diagnosis of EC is difficult because of its nonspecific nature and rarity. Therefore, the disease should be kept in mind for making the diagnosis of EC.

Consequently, even though EC is a rare cause of LGIB, it should be considered in patients with LGIB. EC may present severe complication; therefore, once it is diagnosed, treatment should be initiated to prevent serious complication.

**Ethics Committee Approval:** N/A.

**Informed Consent:** Written informed consent was obtained from the patient who participated in this study.

**Peer-review:** Externally peer-reviewed.

**Author contributions:** Concept - A.K.; Design - A.K.; Supervision - S.B.; Resource - S.B.; Materials - A.K., N.G.; Data Collection &/or Processing - A.K.; Analysis &/or Interpretation - A.O.Y., S.B.; Literature Search - A.K.; Writing - A.K.; Critical Reviews - A.O.Y.

**Address for Correspondence:** Ayşe Kefeli, Department of Gastroenterology, Siirt State Hospital, Siirt, Turkey  
E-mail: aysekefeli@hotmail.com

**Received:** May 28, 2015

**Accepted:** May 29, 2015

**Available Online Date:** July 24, 2015

© Copyright 2015 by The Turkish Society of Gastroenterology • Available online at [www.turkjgastroenterol.org](http://www.turkjgastroenterol.org) • DOI: 10.5152/tjg.2015.0180

**Conflict of Interest:** No conflict of interest was declared by the authors.

**Financial Disclosure:** The authors declared that this study has received no financial support.

**Ayşe Kefeli<sup>1</sup>, Abdullah Özgür Yeniova<sup>2</sup>, Sebahat Başyigit<sup>3</sup>, Nedim Güneş<sup>4</sup>**

<sup>1</sup>Department of Gastroenterology, Siirt State Hospital, Siirt, Turkey

<sup>2</sup>Department of Gastroenterology, Gaziosmanpaşa University Faculty of Medicine, Tokat, Turkey

<sup>3</sup>Department of Gastroenterology, Keçiören Training and Research Hospital, Ankara, Turkey

<sup>4</sup>Department of Pathology, Siirt State Hospital, Siirt, Turkey

## REFERENCES

1. Park EJ, Kim HS, Oh HJ. Eosinophilic gastroenteritis as unusual manifestation of multiple mesenteric lymph node enlargements and recurrent diarrheas. Turk J Gastroenterol 2015; 26: 286-7. [\[CrossRef\]](#)
2. Kocak G, Kocak E, Akbal E, Sen H, Erbag G, Erdoğan C. Eosinophilic colitis: a rare cause of lower gastrointestinal bleeding in an elderly adult. J Am Geriatr Soc 2014; 62: 2016-7. [\[CrossRef\]](#)
3. Okpara N, Aswad B, Baffy G. Eosinophilic colitis. World J Gastroenterol 2009; 15: 2975-9. [\[CrossRef\]](#)
4. Ertugrul I, Ulker A, Turhan N, Daglı U, Sasmaz N. Eosinophilic colitis as an unusual cause of severe bloody diarrhea. Turk J Gastroenterol 2008; 19: 54-6.