



A case of upper extremity thrombosis in patient with ulcerative colitis

To the Editor

Ulcerative colitis (UC) is an idiopathic inflammatory disorder of the colon. Vascular thrombosis is a rare extra-intestinal manifestation of UC. Deep venous thrombosis of lower extremities and pulmonary embolism are the most common thrombotic complications in UC, however upper extremity thrombosis is quite rare (1).

A 58-year-old man with UC was admitted with acute onset pain along with swelling of the left upper extremity and left side of the neck. Doppler ultrasound of the left upper extremity and neck revealed extensive thrombosis (Figure 1). Routine blood tests gave normal results except for a high erythrocyte sedimentation rate, C-reactive protein, hyperfibrinogenemia, anemia, and a significantly elevated level of lipoprotein(a) (90.5 mg/dL). A thrombophilia work-up including antiphospholipid antibody, lupus anticoagulant, homocysteine, factor VIII, D-dimer, fibrinogen, proteins C and S, antithrombin III, PT G20210A, factor V Leiden (FVL) and methylene tetrahydrofolate reductase (MTHFR) were performed. The work-up was negative except for a high level of homocystein (80 mg/dL). Genetic evaluation showed heterozygous for FVL and PT gene mutations and homozygosity for the mutation C677T of the MTHFR gene. The patient was admitted to the hospital and started on low molecular weight heparin. The patient's left arm oedema improved gradually and he had no complaints after the third month of treatment.

We identified only one other reported case of upper extremity thrombosis with UC (1). Some authors suggested that the increased incidence of thromboembolic events in UC may be caused by an increased frequency of thrombophilic mutations (2). Other factors that may contribute to thrombosis including chronic inflammation, dehydration, decreased fibrinolytic activity

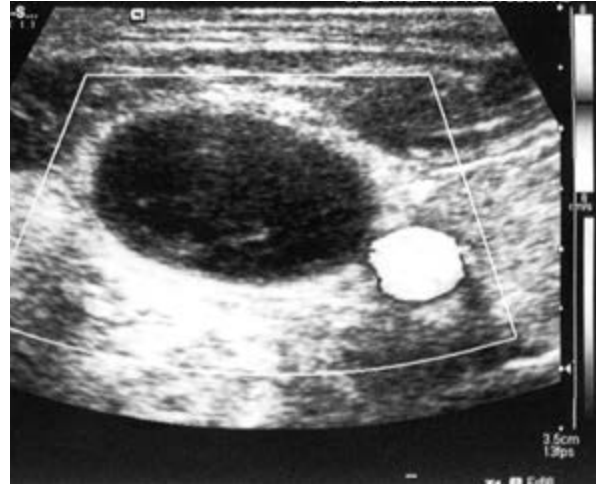


Figure 1. Doppler ultrasound of the left upper extremity and neck revealed extensive thrombosis.

and hyperhomocysteinemia have also been described in IBD (3). But recently found that homozygous MTHFR enzyme c677 on the risk of thrombosis increased risk only 10-20% in normal population (4). In our country Yasa et al. (5) showed that any correlation between IBD and most common hereditary thrombophilic factors. In conclusion thrombophilic mutations may increase the tendency to thrombosis in IBD. But we see that the cause of thrombosis can not attribute only to this mutation. In conclusion we thought that thromboembolic events in IBD are multifactorial including thrombophilic mutations, chronic inflammation, decreased fibrinolytic activity, immobilization, use of corticosteroids, smoking and use of oral contraceptives. We need more case control series of patients complicated with venous thrombosis in order to understand the underlying mechanism of thromboembolic events in IBD.

Informed Consent: Written informed consent was obtained from patient who participated in this study.

Peer-review: Externally peer-reviewed.

Address for Correspondence: İbrahim Halil Türkbeyler, Department of Internal Medicine, School of Medicine, Gaziantep, Turkey
E-mail: turkbeyler@mynet.com

Received: February 28, 2013 **Accepted:** April 09, 2013

© Copyright 2015 by The Turkish Society of Gastroenterology • Available online at www.turkjgastroenterol.org • DOI: 10.5152/tjg.2015.5082

Author contributions: Concept - İ.H.T.; Design - M.S.D.; Supervision - A.K.; Resource - T.B.; Materials - T.B.; Data Collection&/or Processing - O.Z.; Analysis&/or Interpretation - A.K.; Literature Search -M.A.S.; Writing - İ.H.T.; Critical Reviews - A.K.

Conflict of Interest: No conflict of interest was declared by the authors.

**İbrahim Halil Turkbeyler¹, Taner Babacan¹,
M. Sait Dağ², Musa Aydın², Orhan Zengin¹,
M. Akif Sarıca³, Abdurrahman Kadayıfçı²**

¹Department of Internal Medicine, School of Medicine, Gaziantep, Turkey

²Department of Gastroenterology, School of Medicine, Gaziantep, Turkey

³Department of Radiology, School of Medicine, Gaziantep, Turkey

REFERENCES

1. Haumer M, Teml A, Dirisamer A, Vogelsang H, Koppensteiner R, Novacek G. Severe ulcerative colitis complicated by an arterial thrombus in the brachiocephalic trunk. *Inflamm Bowel Dis* 2007; 13: 937-8. [\[CrossRef\]](#)
2. Wong T, Nightingale J, Winter M, Muller AF. Spontaneous venous thrombosis in inflammatory bowel disease: relevance of factor V Leiden and the prothrombin gene mutation. *J Thromb Haemost* 2003; 1: 1326-8. [\[CrossRef\]](#)
3. Oldenburg B, Fijnheer R, van der Griend R, van Berge-Henegouwen GP, Koningsberger JC. Homocysteine in inflammatory bowel disease: a risk factor for thromboembolic complications? *Am J Gastroenterol* 2000; 95: 2825-30. [\[CrossRef\]](#)
4. Zheng YZ, Tong J, Do XP, Pu XQ, Zhou BT. Prevalence of methylenetetrahydrofolate reductase C677T and its association with arterial and venous thrombosis in the Chinese population. *Br J Haematol.* 2000; 109: 870-4.
5. Yasa MH, Bolaman Z, Yukselen V, Kadikoylu G, Karaoglul AO, Batun S. Factor V Leiden G1691A, prothrombin G20210A, and MTHFR C677T mutations in Turkish inflammatory bowel disease patients. *Hepatogastroenterology* 2007, 54: 1438-42. [\[CrossRef\]](#)