

# Fascin expression and its potential significance in gastrointestinal stromal tumors

Ayhan ÖZCAN<sup>1</sup>, Yıldırım KARSLIOĞLU<sup>1</sup>, Armağan GÜNAL<sup>1</sup>, A. Hakan ÇERMİK<sup>2</sup>, Bülent KURT<sup>1</sup>,  
Önder ÖNGÜRÜ<sup>1</sup>

Department of <sup>1</sup>Pathology, Gülhane Military Medical Academy, School of Medicine, Ankara  
Department of <sup>2</sup>Pathology, Military Hospital, Etimesgut, Ankara

**Background/aims:** Fascin is an actin-bundling protein that is important in cell motility. Fascin expression has been shown to have a potential role in tumor progression for some epithelial tumors. However, there are only a few studies related to its expression in mesenchymal tumors. We investigated fascin expression in gastrointestinal stromal tumors. **Methods:** Thirty gastrointestinal stromal tumors, which were very low (n=6), low (n=2), moderate (n=4), and high (n=18) risk, constituted our series. Immunohistochemical expression of fascin was studied in all cases. **Results:** Immunoreactivity was observed in only five cases, all of which were in the high-risk group. The remaining cases (25/30) showed no immunoreactivity, and the difference did not seem statistically important (p=0.261). Fascin expression was stronger in epithelioid cells than spindle-shaped cells (p=0.003). In addition, gastrointestinal stromal tumors in the small bowel showed higher fascin expression than those in the other localizations (p=0.043). **Conclusions:** It seems that anatomic localization and the tumor cell type of gastrointestinal stromal tumors show statistically significant differences with regard to fascin expression. Although our series is limited, we think that fascin should be considered as a marker that is worthy of further study for its potential usage as a prognostic indicator in gastrointestinal stromal tumors.

**Key words:** Gastrointestinal stromal tumor, immunohistochemistry, fascin, tumor progression, prognosis

## Gastrointestinal stromal tümörlerde fascin ekspresyonu ve potansiyel önemi

**Amaç:** Fascin, hüresel motilitede rol oynayan bir aktin desteleyici proteindir. Fascin ekspresyonunun bazı epitelyal tümörlerde, tümörün ilerlemesinde önemli rolü olduğu gösterilmiştir. Ancak, mezenkimal tümörlerdeki ekspresyonu hakkında çok az çalışma vardır. Bu çalışmada gastrointestinal stromal tümörlerdeki fascin ekspresyonu araştırılmıştır. **Yöntem:** Olgu serimiz çok düşük (n=6), düşük (n=2), orta (n=4) ve yüksek (n=18) risk grubunda bulunan toplam 30 gastrointestinal stromal tümör olgusundan oluşmaktadır. Bütün olgularda fascin ekspresyonu immünohistokimyasal yöntemle araştırılmıştır. **Bulgular:** İmmünoaktivite yalnızca yüksek risk grubundaki beş olguda görülmüştür. Geri kalan olgularda (25/30) immünoaktivite izlenmemiştir ve arada istatistiksel olarak anlamlı fark bulunmamıştır (p=0.261). Fascin ekspresyonu, epiteloïd görünümli hücrelerde iğsi şekilli hücrelerden daha güçlü izlenmiştir (p=0.003). Ayrıca, ince bağırsak yerleşimli gastrointestinal stromal tümörlerde diğer yerleşim yerlerindeki ne oranla daha yüksek ekspresyon saptanmıştır (p=0.043). **Sonuç:** Gastrointestinal stromal tümörlerde tümörün anatomik yerleşimi ve tümör hücrelerinin görünümü ile fascin ekspresyonu arasındaki ilişki istatistiksel yönden anlamlı gibi görünmektedir. Olgu sayımız sınırlı olmasına rağmen, fascin'in gastrointestinal stromal tümörlerde prognostik bir belirleyici olarak kullanılması amacıyla daha geniş kapsamlı çalışmalar için kayda değer bir belirtçe olabileceğini düşünmekteyiz.

**Anahtar kelimeler:** Gastrointestinal stromal tümör, immünohistokimya, fascin, tümör progresyonu, prognoz

## INTRODUCTION

Gastrointestinal stromal tumors (GISTs) are the most common mesenchymal tumors of the gastro-

intestinal tract (1-13). GISTs most commonly arise in the stomach (51%), and affect to a much les-

**Address for correspondence:** Ayhan ÖZCAN  
Gülhane Military Medical Academy  
Department of Pathology, Etlik, Ankara, Turkey  
Phone: + 90 312 304 59 84  
E-mail: aozcan06018@yahoo.com

**Manuscript received:** 23.07.2010 **Accepted:** 07.01.2011

*Turk J Gastroenterol* 2011; 22 (4): 363-368  
doi: 10.4318/tjg.2011.0240

\* This study was presented as a poster at the 18<sup>th</sup>  
Turkish National Congress of Pathology,  
October 25-29, 2008, Belek, Antalya, Turkey

ser extent the remaining parts of the gastrointestinal tract as follows: small intestine (36%), colon (7%), rectum (1%), or esophagus (1%).

Most GISTs are immunoreactive for CD 117 (c-kit) and CD 34, and are typically negative for S-100 protein and desmin (1-14). CD 117 positivity is present in all histological variants including benign and malignant GISTs of different sites. There are only a few reports stating that a small number of GISTs might be negative for CD 117 (12,13). It is known that Ki-67 (MIB-1) expression in a GIST of more than 10% likely indicates poor prognosis (2,9).

Tumor progression is characterized by both the loss of cell-cell and cell-matrix interactions as well as the invasion of the surrounding tissues by tumor cells. All cells are capable of organizing their protoplasmic actin filaments into cross-linked structures that influence cell shape, proliferation, adhesion, motility, and intracellular signaling pathway. Numerous actin-bundling proteins have been described, such as villin, fimbrin, ezrin, spectrin, filamin, and fascin (15-17).

Fascin is a 55 kDa cross-linking protein that localizes the core actin bundles of spikes and filopodia at the leading edge of migratory cells (15-30). Fascin promotes the formation of tightly packed parallel bundles with F-actin (16,19,21). There are three forms of fascin: fascin-1 (also known as fascin), fascin-2 (retinal fascin) and fascin-3 (testicular fascin) (16,19,21). Fascin has a role in the organization of actin-based structures that function in cell-cell and cell-matrix interactions and motility. Fascin binds beta-catenin, a molecule that is not only an important part of the cell-cell interaction, but also a major signaling molecule in the Wnt pathway (15). It has been proposed that fascin might be expected to behave like an anti-oncogene because of its reducing effect on the cytoplasmic pool of soluble beta-catenin (15). Fascin is expressed in normal mesenchymal, endothelial, dendritic, and neuronal cells, but not in normal simple columnar epithelia of the biliary duct, breast, colon, ovary, pancreas, and stomach epithelia (16,19). The expression of fascin in epithelial neoplasms, on the other hand, has recently been described. In normal epithelial cells, fascin expression is usually present in a very low amount but is often upregulated in several types of human neoplasms, such as ovarian, breast, pancreatic, lung, skin, colon, stomach, and esophagus tumors (20-30). It is not yet known how and why fascin is upregulated in carcinoma cells. Additionally, it is not clear

whether the increased fascin protein expression by carcinomas is related to transcriptional or post-transcriptional events, or if the same mechanism is involved in carcinomas of different organs (19).

There are a limited number of studies regarding the role of fascin expression in spindle cell tumors (31). While fascin was evaluated as a potential marker of dendritic cell neoplasms, it does not seem to be a useful marker in the diagnosis of other spindle cell tumors (31). We aimed to investigate fascin expression with regard to anatomic localizations, tumor invasiveness, prognostic risk groups, and predominant morphological features or cell types of GISTs.

## MATERIALS AND METHODS

A total of 30 GIST cases diagnosed from the resection materials between 1995 and 2008 were retrieved from the archives of the Department of Pathology, Gülhane Military Medical Academy. Our cases were categorized into groups as follows: 6 cases, very low risk; 2 cases, low risk; 4 cases, moderate risk; and 18 cases, high risk (Table 1). The rates of metastases or tumor-related death in GISTs were grouped by Miettinen and Lasota (7) classification according to tumor location, tumor size and mitotic rate. The distribution of our cases according to this new classification is demonstrated in Table 2.

In order to check and confirm the diagnosis of GIST, an immunohistochemical panel consisting of six antibodies against CD 117, CD 34, smooth muscle actin (SMA), desmin, S-100 protein, and Ki-67 was performed on all cases, and reassessed by one of the participants (A.Ö.) (10). The most suitable paraffin block for fascin immunostaining (FCN01; 1: 100 dilution; NeoMarkers, Fremont, CA, USA) was selected by reexamining 3-15 hematoxylin-eosin (H&E)-stained slides. For demonstrating the fascin expression, standard 5- $\mu$ m sections were obtained and deparaffinized with xylene and rehydrated in graded alcohols. Positive cases

**Table 1.** Fascin expression in GISTs according to the tumor risk groups

Tumor risk groups	Staining Positive / Total Cases (%)	Statistical Significance
Very low	0/6 (0)	p=0.261
Low	0/2 (0)	
Moderate	0/4 (0)	
High	5/18 (31)	
TOTAL	5/30 (17)	

**Table 2.** Fascin expression in GISTs according to new Miettinen and Lasota (7) risk classification based on mitotic index, size and tumor localizations

Group	Tumor Parameters		Tumor localizations				TOTAL	p
	Tumor Size (cm)	Mitotic Rate (in 50 HPFs)	Stomach	Jejunum	Duodenum	Rectum		
1	≤2	≤5	0/2	ND	ND	ND	0/2	0.242
2	>2- ≤5	≤5	0/4	ND	ND	ND	0/4	
3a	>5-≤10	≤5	0/2	0/2	ND	ND	0/4	
3b	>10	≤5	ND	ND	ND	ND	ND	
4	≤2	>5	ND	ND	ND	ND	ND	
5	>2-≤5	>5	0/4	1/1	ND	0/1	1/6	
6a	>5- ≤10	>5	1/4	1/1	2/3	0/2	4/10	
6b	>10	>5	0/1	0/3	ND	ND	0/4	
TOTAL			1/17	2/7	2/3	0/3	5/30	
p				0.043				

ND: Not determined. HPF: High-power field.

for fascin were also stained by SMA (Ab1; 1: 200 dilution; NeoMarkers, Fremont, CA, USA) and muscle specific antigen (MSA) (HHF35; 1: 100 dilution; NeoMarkers, Fremont, CA, USA). All immunohistochemical staining was carried out using Lab Vision Autostainer 480 (Lab Vision Products, Thermo Fisher Scientific, Fremont, CA, USA).

Each section was thoroughly examined to assess and record both the intensity and the extension of fascin immunolabeling. A positive result was defined as strong staining in at least 10% of tumor cells. Besides stained neoplastic cells, we noticed individually highlighted cells throughout the tumors. Because of their slightly different morphology and the pattern of staining, we interpreted these cells as the entrapped dendritic cells. Dendritic cells have cytoplasmic processes that are rich in fascin and somewhat stellate in morpho-

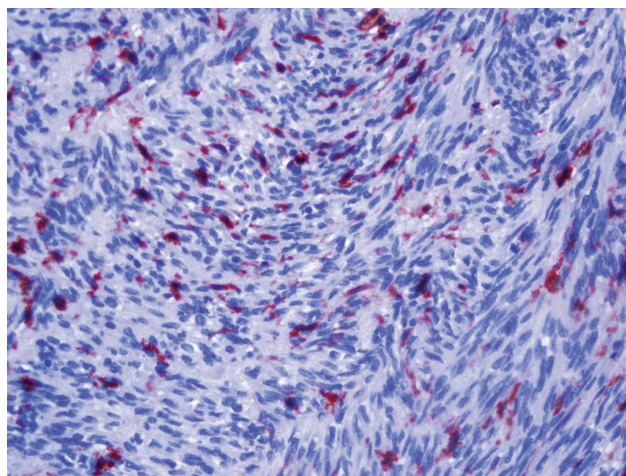
logy. These are the most helpful clues for distinguishing them from stained tumor cells (Figure 1).

Either endothelial or dendritic cells in the samples were used as internal positive controls [4]. Nonimmune serum was used as the negative control.

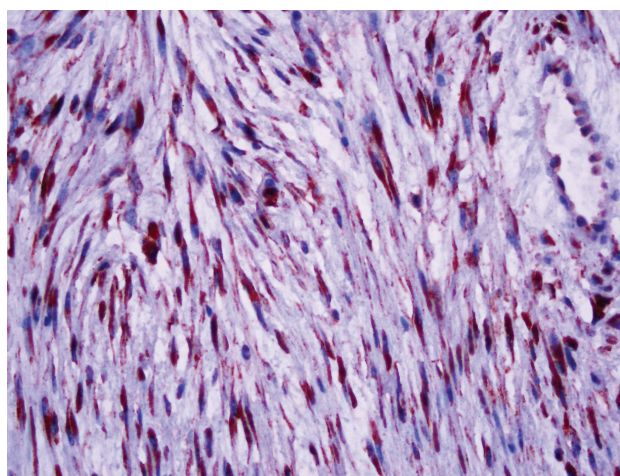
The differences between groups were investigated for statistical significance by the chi-square test, with  $p < 0.05$  as the cut-off point.

**RESULTS**

Fascin expression was noted in 17% (5/30) of the cases. All of the fascin-expressing GISTs were in the high-risk group (5/16), while the remaining high-risk as well as low- and moderate-risk GISTs showed no convincing immunoreactivity. The degree of staining was either moderate or strong (Figure 2). According to the basic four-level risk gro-



**Figure 1.** Fascin expression in dendritic cells that were scattered throughout tumor cells (H&E, x400).



**Figure 2.** Diffuse and strong fascin expression in spindle-shaped tumor cells (H&E, x400).

ups (Table 1) and eight-level groups based on the rates of metastases or tumor-related death (Table 2), the results seemed not statistically significant ( $p=0.261$  and  $p=0.242$ , respectively).

Fascin expression in GISTs composed of purely spindle cells was 4.5% (1/22) (Table 3). On the other hand, expression in the tumors composed of both spindle and epithelioid cells was around 50% (4/8) (Table 3). We observed that the intensity of staining was especially more conspicuous in epithelioid cells when compared to spindle cells. This finding seemed statistically significant ( $p=0.003$ ). We also noted that the epithelioid cells, when present, were almost always positively labelled by fascin antibody (Figure 3).

Fascin expression rates with respect to the localization of individual tumors are presented in Tables 1 and 2. No fascin expression was detected in GISTs from the large bowel (rectum) (0/3). We noticed a tendency of higher level of expression in the small bowel (jejunum and duodenum)-derived GISTs than those from the other localizations, and the difference was also statistically significant ( $p=0.043$ ).

All the five fascin-positive tumors were demonstrated to have some extent of infiltration into the

nearby soft tissues and/or organs. One of the jejunal cases showed recurrence just six months after the primary surgical removal of the tumor.

While epithelioid tumor cells were mostly positive for SMA as well, no immunoreactivity in spindle cells was detected. All fascin-positive cases were found negative for MSA.

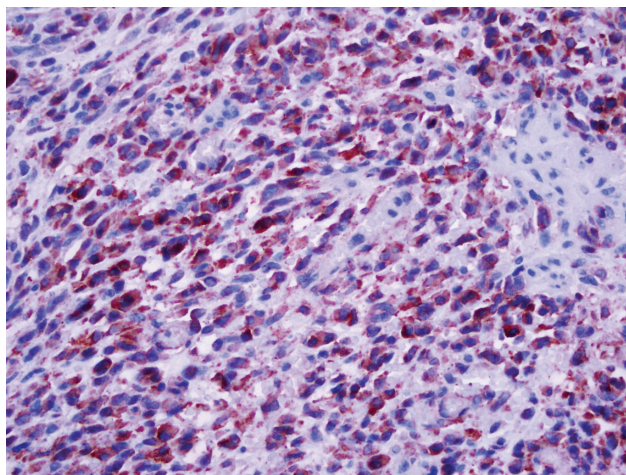
## DISCUSSION

Most of the gastrointestinal mesenchymal tumors, previously diagnosed as smooth muscle tumors, are now classified as GISTs. GISTs have a potential to show a wide variety of phenotypic differentiation including myoid, neural, mixed, and null morphology. Therefore, a broad immunohistochemical panel including muscular and neural markers such as CD 117 (c-kit), CD 34, SMA, desmin, and S-100 protein are required in their differential diagnosis. GISTs are usually positive for CD 117 (c-kit) and negative for S-100 and desmin (3,5-7,13). A small percentage of CD 117-negative GISTs are known to be positive for platelet-derived growth factor receptor-alpha (PDGFR-A), a receptor tyrosine kinase similar to CD 117 (5-7). Approximately 60-99% of all GISTs are also positive for CD 34, which is a progenitor-cell antigen mainly expressed by endothelial cells and in some subsets of fibroblasts and their tumors (6,7,13). About 10-30% of GISTs show a malignant clinical course (6). Pathologically, tumor location, size and mitotic activity are independent prognostic factors for GISTs (3,5).

Fascin is an actin-bundling protein that is expressed in normal mesenchymal, endothelial, dendritic, and neuronal cells but not in normal epithelia (16). Many types of transformed epithelial cell lines and several epithelial tumors have been shown to express fascin (20-30). Some studies have suggested that the degree of fascin expression is well correlated with tumor stage, grade, lymph node involvement, and recurrence rate (22,23,29). However, this kind of relationship of fascin expression in spindle cell tumors has not yet been very well evaluated or documented. Grogg *et al.* (31) suggested that fascin is a potentially important marker for dendritic cell neoplasms, but it does not seem to be a useful marker in the diagnosis of other spindle cell tumors. In this study, we investigated the fascin expression in GISTs against their anatomic locations, invasiveness, prognostic risk groups, and the predominant morphology of neoplastic cells, either epithelioid, spindle or mixed.

**Table 3.** Fascin expression in GISTs according to cell types

Tumor cell types	Staining Positive / Total Cases (%)	Statistical Significance
Spindle	1/22 (5)	$p=0.003$
Spindle + Epithelioid	4/8 (50)	



**Figure 3.** Diffuse and strong fascin expression in spindle-shaped and epithelioid tumor cells (H&E, x400).

Grogg et al. (31) also investigated fascin expression in GISTs, and three cases (3/13 or 23%) showed only focal staining, while only one case (1/13 or 8%) showed diffuse expression. Similarly, we found that fascin expression is low in GISTs, in general (17%). Our results according to basic risk groups (Table 1) and groups based on tumor progression (Table 2) suggested that fascin expression in GISTs did not show any statistically significant differences ( $p=0.261$  and  $p=0.242$ , respectively). However, fascin expressions with regard to tumor cell types and localizations seemed statistically significant ( $p=0.003$  and  $p=0.043$ , respectively). We also noticed focal or individually fascin-labeled cells in some GISTs. We think that such cells, which represent only a small percentage (generally below 10%) of the entire tumor cells and show relatively weak staining (1+) compared to the intensely stained neoplastic cells, might be dendritic cells entrapped by the neoplastic growth. Our observation is supported by the study of Cameron et al. (32). They also demonstrated that dendritic cells were scattered between the GIST cells and were fascin-positive. In that case, the focally stained cells in GISTs, which were mentioned in the paper by Grogg et al. (31), like in our cases, should also be dendritic cells. Thus, we selectively ignored their positive staining and used

them instead as positive internal control, among the positivity in endothelial cells.

Smooth muscle actin (SMA) is reported positive in 25% of GISTs (8). Seidal et al. (9) found that MSA was weakly positive in 17% (11/64 cases) in GISTs. Because of its actin-bundling nature, we limited the actin immunoprofiling using SMA and MSA in only fascin-positive cases. There was no staining for MSA in our cases. While epithelioid cells showed SMA expression, there was no or only focal and weak staining in spindle cells. SMA expression was determined in fascin-positive cells and especially with epithelioid morphology. This difference might originate from different epitope or isomers of actins.

In summary, our results indicated that the fascin expression was mostly moderate and limited only in high-risk GISTs. The other risk groups of GISTs showed practically no immunoreactivity with fascin. Staining intensity of epithelioid cells was significantly higher than that of the spindle cells. We noticed a tendency of higher level of expression in the small bowel (duodenum and jejunum) GISTs than those from the other localizations. These findings suggest that fascin expression in GISTs might be a well-correlated marker with the risk groups that are related to the tumor progression and aggressiveness.

## REFERENCES

- Appelman HD. Smooth muscle tumors of the gastrointestinal tract. What we know that Stout didn't know. *Am J Surg Pathol* 1986; 10: 83-99.
- Bearzi I, Mandolesi A, Arduini F, et al. Gastrointestinal stromal tumor. A study of 158 cases: clinicopathological features and prognostic factors. *Anal Quant Cytol Histol* 2006; 28: 137-47.
- Hornick JL, Fletcher CD. The role of KIT in the management of patients with gastrointestinal stromal tumors. *Hum Pathol* 2007; 38: 679-87.
- Kindblom LG, Remotti HE, Aldenborg F, Meis-Kindblom JM. Gastrointestinal pacemaker cell tumor (GIPACT); gastrointestinal stromal tumors show phenotypic characteristics of the interstitial cells of Cajal. *Am J Pathol* 1998; 152: 1259-69.
- Miettinen M, Sobin LH, Lasota J. Gastrointestinal stromal tumors of the stomach: a clinicopathologic, immunohistochemical, and molecular genetic study of 1765 cases with long-term follow-up. *Am J Surg Pathol* 2005; 29: 52-68.
- Miettinen M, Makhlof H, Sobin LH, et al. Gastrointestinal stromal tumors of the jejunum and ileum: a clinicopathologic, immunohistochemical, and molecular genetic study of 906 cases before imatinib with long-term follow-up. *Am J Surg Pathol* 2006; 30: 477-89.
- Miettinen M, Lasota J. Gastrointestinal stromal tumors: pathology and prognosis at different sites. *Semin Diagn Pathol* 2006; 23: 70-83.
- Miettinen M, Lasota J. Gastrointestinal stromal tumors: review on morphology, molecular pathology, prognosis, and differential diagnosis. *Arch Pathol Lab Med* 2006; 130: 1466-78.
- Seidal T, Edvardsson H. Expression of c-kit (CD117) and Ki67 provides information about the possible cell of origin and clinical course of gastrointestinal stromal tumours. *Histopathology* 1999; 34: 416-24.
- Ozcan A, Karslioglu Y, Kurt B, et al. Quantitative evaluation of immunohistochemical staining in gastrointestinal stromal tumors. *Anal Quant Cytol Histol* 2007; 29: 159-65.
- Tran T, Davila J, El-Serag HB. The epidemiology of malignant gastrointestinal stromal tumors: an analysis of 1,458 cases from 1992 to 2000. *Am J Gastroenterol* 2005; 100: 162-8.
- Tzen CY, Mau BL. Analysis of CD 117-negative gastrointestinal stromal tumors. *World J Gastroenterol* 2005; 11: 1052-5.
- Yamaguchi U, Hasegawa T, Masuda T, et al. Differential diagnosis of gastrointestinal stromal tumor and other spindle cell tumors in the gastrointestinal tract based on immunohistochemical analysis. *Virchows Arch* 2004; 445: 142-50.
- Robinson TL, Sircar K, Hewlett BR, et al. Short communication; gastrointestinal stromal tumors may originate from a subset of CD34 positive interstitial cells of Cajal. *Am J Pathol* 2000; 156: 1157-63.

15. Tao YS, Edwards RA, Tubb B, et al. Beta-catenin associates with the actin-bundling protein fascin in a noncadherin complex. *J Cell Biol* 1996; 134: 1271-81.
16. Kureishy N, Sapountzi V, Prag S, et al. Fascins, and their roles in cell structure and function. *Bioessays* 2002; 24: 350-61.
17. Bryan J, Edwards R, Matsudaira P, et al. Fascin, an echinoid actin-bundling protein, is a homolog of the *Drosophila* singed gene product. *Proc Natl Acad Sci* 1993; 90: 9115-9.
18. Adams JC. Roles of fascin in cell adhesion and motility. *Curr Opin Cell Biol* 2004; 16: 590-6.
19. Hashimoto Y, Skacel M, Adams JC. Roles of fascin in human carcinoma motility and signaling: prospects for a novel biomarker? *Int J Biochem Cell Biol* 2005; 37: 1787-804.
20. Goncharuk VN, Ross JS, Carlson JA. Actin-binding protein fascin expression in skin neoplasia. *J Cutan Pathol* 2002; 29: 430-8.
21. Buda A, Pignatelli M. Cytoskeletal network in colon cancer: from genes to clinical application. *Int J Biochem Cell Biol* 2004; 36: 759-65.
22. Hashimoto Y, Shimada Y, Kawamura J, et al. The prognostic relevance of fascin expression in human gastric carcinoma. *Oncology* 2004; 67: 262-70.
23. Hashimoto Y, Ito T, Inoue H, et al. Prognostic significance of fascin overexpression in human esophageal squamous cell carcinoma. *Clin Cancer Res* 2005; 11: 2597-605.
24. Hashimoto Y, Skacel M, Lavery IC, et al. Prognostic significance of fascin expression in advanced colorectal cancer: an immunohistochemical study of colorectal adenomas and adenocarcinomas. *BMC Cancer* 2006; 6: 241.
25. Grothey A, Hashizume R, Sahin AA, McCrea PD. Fascin, an actin-bundling protein associated with cell motility, is upregulated in hormone receptor negative breast cancer. *Br J Cancer* 2000; 83: 870-3.
26. Hu W, McCrea PD, Deavers M, et al. Increased expression of fascin, motility associated protein, in cell cultures derived from ovarian cancer and in borderline and carcinomatous ovarian tumors. *Clin Exp Metastasis* 2000; 18: 83-8.
27. Jawhari AU, Buda A, Jenkins M, et al. Fascin, an actin-bundling protein, modulates colonic epithelial cell invasiveness and differentiation in vitro. *Am J Pathol* 2003; 162: 69-80.
28. Maitra A, Iacobuzio-Donahue C, Rahman A, et al. Immunohistochemical validation of a novel epithelial and a novel stromal marker of pancreatic ductal adenocarcinoma identified by global expression microarrays: sea urchin fascin homolog and heat shock protein 47. *Am J Clin Pathol* 2002; 118: 52-9.
29. Pelosi G, Pastorino U, Pasini F, et al. Independent prognostic value of fascin immunoreactivity in stage I nonsmall cell lung cancer. *Br J Cancer* 2003; 88: 537-47.
30. Puppa G, Maisonneuve P, Sonzogni A, et al. Independent prognostic value of fascin immunoreactivity in stage III-IV colonic adenocarcinoma. *Br J Cancer* 2007; 96: 1118-26.
31. Grogg KL, Macon WR, Kurtin PJ, Nascimento AG. A survey of clusterin and fascin expression in sarcomas and spindle cell neoplasms: strong clusterin immunostaining is highly specific for follicular dendritic cell tumor. *Mod Pathol* 2005; 18: 260-6.
32. Cameron S, Haller F, Dudas J, et al. Immune cells in primary gastrointestinal stromal tumors. *Eur J Gastroenterol Hepatol* 2008; 20: 327-34.