

REFERENCES

1. Gaspari R, Annetta MG, Cavaliere F, et al. Unusual presentation of leptospirosis in the late stage of pregnancy. *Minerva Anestesiol* 2007; 73: 429-32.
2. Rahman TM, Wendon J. Severe hepatic dysfunction in pregnancy. *Q J Med* 2002; 95: 343-57.
3. Sheehan HL. Jaundice in pregnancy. *Am J Obstet Gynecol* 1961; 81: 427-40.
4. Kunelis CT, Peters JL, Edmondson HA. Fatty liver of pregnancy and its relationship to tetracycline therapy. *Am J Obstet Gynecol* 1965; 33: 359-77.
5. Gallwas J, Ackermann H, Friedmann W. Thrombotic thrombocytopenic purpura-a rare and difficult differential diagnosis to HELLP syndrome in late pregnancy. *Z Geburtshilfe Neonatol* 2008; 212(2): 64-6.
6. Shibagaki Y, Fujita T. Thrombotic microangiopathy in malignant hypertension and hemolytic uremic syndrome (HUS)/ thrombotic thrombocytopenic purpura (TTP): can we differentiate one from the other? *Hypertens Res* 2005; 28: 89-95.

Emel Ebru ÖZÇİMEN¹, Ayla UÇKUYU¹,
Gülhan Kanat ÜNLER²,
Hüseyin Savaş GÖKTÜRK², Uğur YILMAZ²

Departments of ¹Obstetrics and Gynecology ²Gastroenterology,
Başkent University School of Medicine, Konya

A rare cause of cholangitis: *Fasciola hepatica*

Nadir bir kolanjit nedeni: *Fasciola hepatica*

To the Editor,

Fascioliasis is a zoonotic disease caused by liver flukes (1.) Although Turkey is regarded as meso-endemic for the disease, there are few cases reported (2, 6, 7).

The disease has a broad clinical spectrum ranging from an acute hepatic phase to a chronic biliary phase. The diagnosis of fascioliasis can be established when the eggs of *Fasciola hepatica* are found in feces, duodenal aspirates or bile or by using various serological tests (3, 14, 15). Imaging studies are also helpful (8, 16-18).

A 58-year-old female patient admitted to the emergency department with fatigue, malaise, loss of appetite, and abdominal pain. Her medical history revealed hypertension and hyperlipidemia for two years. On physical examination, she had pain on the right upper quadrant and her scleras were icteric. Laboratory investigation results were as follows: glucose: 127 mg/dl, aspartate aminotransferase: 541 U/L, alanine aminotransferase: 886 U/L,

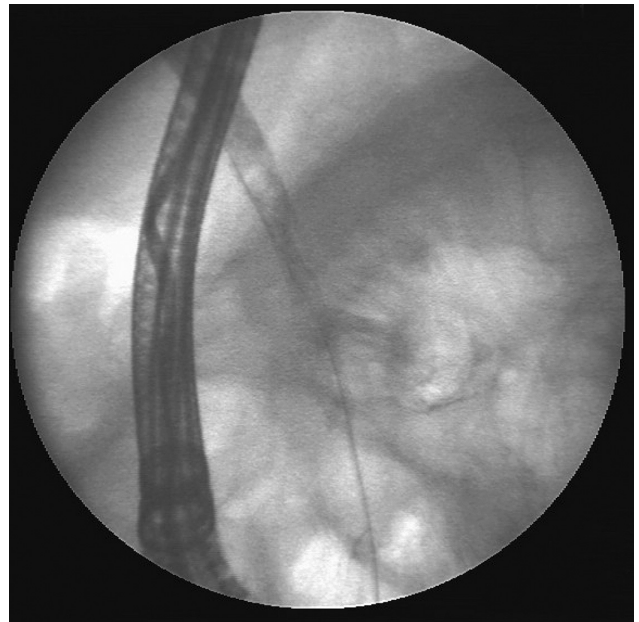

Figure 1. ERCP demonstrated dilatation in intrahepatic bile ducts and common bile duct.

Address for correspondence: Fatih ASLAN
İzmir Atatürk Eğitim ve Araştırma Hastanesi, İzmir, Turkey

Manuscript received: 09.07.2009 Accepted: 15.01.2010

doi: 10.4318/tjg.2010.0115

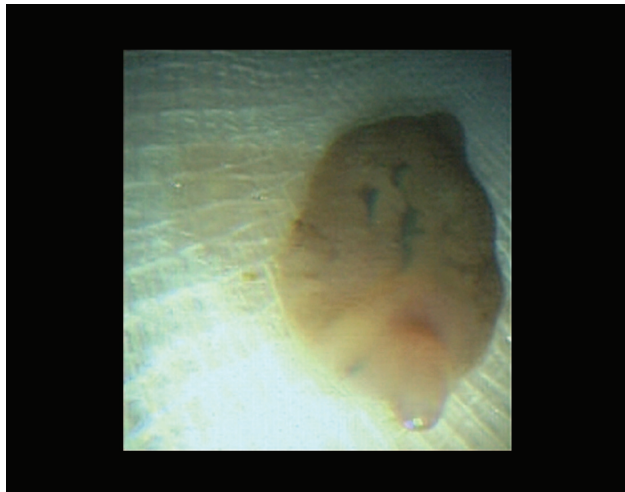


Figure 2. Extracted live *Fasciola hepatica*.

gamma glutamyl transferase: 659 U/L, alkaline phosphatase: 254 U/L, total bilirubin 5.4 mg/dl, conjugated bilirubin 3.39 mg/dl, white blood cell count: 12.7 K/mm³, polymorphonuclear leukocyte (PNL): 4400 (37.4%), lymphocyte: 4400 (34.6%), monocyte: 563 (4.42%), eosinophil count: 3200 (25.1%), hemoglobin: 15 g/dl, platelet count: 297.0 K/mm³: 351,000, C-reactive protein: 53 mg/L, and erythrocyte sedimentation rate: 44 mm/h.

She tested negative for HBsAg, anti-hepatitis A virus (HAV)-IgM, anti-hepatitis B virus (HBV)-IgM, anti-hepatitis C virus (HCV), anti-Rubella IgM, anti-cytomegalovirus (CMV)-IgM, anti-toxoplasma IgM, anti-hepatitis E, Epstein-Barr vi-

rus (EBV)-VCA IgM, antinuclear antibody (ANA), antimitochondrial antibody (AMA), ASMA, and anti-liver-kidney microsomal antibody (LKM).

Ultrasonography revealed mild dilatation in intrahepatic bile ducts and gallbladder stones. Magnetic resonance cholangiopancreatography showed dilatation in intrahepatic and main hepatic ducts and millimetric filling defects in the middle portion of the common bile duct. The patient was considered as acute cholangitis and antibiotherapy (cephoperazone 2 g/day) was started. On the 6th day of treatment, the clinical signs and symptoms improved. Endoscopic retrograde cholangiopancreatography was performed, which revealed dilatation in the intrahepatic bile ducts and common bile duct. Filling defects in the middle portion of the common bile duct were visualized (Figure 1). After a standard sphincterotomy, balloon extraction to the choledochus was performed and two living *Fasciola hepatica* were extracted (Figure 2). Antihelminthic therapy was started and the liver function tests improved in the follow-up. Complete improvement was achieved after the extraction of *F. hepatica* and antihelminthic therapy. Fascioliasis may cause recurrent cholangitis and irreversible secondary biliary cirrhosis if untreated. Fascioliasis should be considered in the differential diagnosis in patients living in rural areas and in those with a history of watercress ingestion, especially when they present with eosinophilia, unexplained obstructive jaundice, recurrent cholangitis, or elevations in transaminases.

REFERENCES

1. Adachi S, Kotani K, Shimizu T, et al. Asymptomatic fascioliasis. *Intern Med* 2005; 44: 1013-5.
2. Mas-Coma MS, Esteban JG, Bargues MD. Epidemiology of human fascioliasis: a review and proposed new classification. *Bull World Health Organ* 1999; 77: 340-6.
3. Turhan O, Korkmaz M, Saba R, et al. Seroepidemiology of fascioliasis in the Antalya region and uselessness of eosinophil count as a surrogate marker and portable ultrasonography for epidemiological surveillance. *Infez Med* 2006; 14: 208-12.
4. Sezgin O, Altintas E, Disibeyaz S, et al. Hepatobiliary fascioliasis: clinical and radiologic features and endoscopic management. *J Clin Gastroenterol* 2004; 38: 285-91.
5. Arjona, R, Riancho, JA, Aguado, JM, et al. Fascioliasis in developed countries: a review of classic and aberrant forms of the disease. *Medicine (Baltimore)* 1995; 74: 13-23.
6. Saba R, Korkmaz M, Inan D, et al. Human fascioliasis. *Clin Microbiol Infect* 2004; 10: 385-7.
7. Hillyer, GV, Soler de, Galanes M, et al. Use of the Falcon assay screening test--enzyme-linked immunosorbent assay (FAST-ELISA) and the enzyme-linked immunoelectrotransfer blot (EITB) to determine the prevalence of human fascioliasis in the Bolivian Altiplano. *Am J Trop Med Hyg* 1992; 46: 603.
8. Kabaalioglu A, Çubuk M, Senol U, et al. Fascioliasis: US, CT, and MRI findings with new observations. *Abdom Imaging* 2000; 25: 400-4.
9. Lim JH, Mairiang E, Ahn GH. Biliary parasitic diseases including clonorchiasis, opisthorchiasis and fascioliasis. *Abdom Imaging* 2008; 33: 157-65.
10. Cevikol C, Karaali K, Senol U, et al. Human fascioliasis: MR imaging findings of hepatic lesions. *Eur Radiol* 2003; 13: 141-8.
11. Aksoy DY, Kerimoğlu U, Oto A, et al. Fasciola hepatica infection: clinical and computerized tomographic findings of ten patients. *Turk J Gastroenterol* 2006; 17: 40-5.

Fatih ASLAN, Emrah ALPER, Zehra AKPINAR, Behlül BAYDAR, Mehmet Kadir AKSÖZ, Zafer BUYRAÇ, Cem ÇEKİÇ, Belkıs ÜNSAL

Department of Gastroenterology, Atatürk Training and Research Hospital, İzmir