









# Clinical report and analysis of 24 cases of multiple magnetic beads foreign body in gastrointestinal tract of children

Xian-Ling Li<sup>1</sup> , Qin-Ming Zhang<sup>2</sup> , Shou-Yan Lu<sup>3</sup> , Ting-Ting Liu<sup>1</sup> , Zi-Ming Yao<sup>1</sup> , Wei-Ping Zhang<sup>1</sup> , Ya-Jun Chen<sup>1</sup> , Long Chen<sup>1</sup> , Fang-Nan Xie<sup>1</sup> 

<sup>1</sup>Department of Surgery, Beijing Children's Hospital, Capital Medical University, National Center for Children's Health, Beijing, China

<sup>2</sup>Department of Surgery, Beijing United Family Hospital, Beijing, China

<sup>3</sup>Department of Surgery, Beijing Aiyuhua Women's and Children's Hospital, Beijing, China

**Cite this article as:** Li XL, Zhang QM, Lu SY, et al. Clinical report and analysis of 24 cases of multiple magnetic beads foreign body in gastrointestinal tract of children. *Turk J Gastroenterol* 2020; 31(11): 819-24.

## ABSTRACT

**Background/Aims:** This study aimed to analyze the data of 24 cases of multiple perforation or obstruction of the digestive tract caused by accidental ingestion of magnetic beads, to improve the understanding of its harmfulness to children and explore the best treatment.

**Materials and Methods:** In total, 24 cases were collected and retrospectively analyzed. These patients were divided into two groups: perforation group and non-perforation group. The medical history, number of magnetic beads, white blood cell (WBC) count, and C-reactive protein (CRP) were analyzed.

**Results:** There was no significant difference in age, gender, medical history, number of magnetic beads, and WBC count between the perforation group and non-perforation group, but there was a significant difference in CRP. After the diagnosis, 70% of the cases underwent laparotomy and perforation repair. All cases recovered smoothly after the operation, and no complications occurred during the follow-up.

**Conclusion:** This study offers diagnosis and treatment methods for the perforation or obstruction of the digestive tract caused by accidental ingestion of magnetic beads and raises the awareness regarding the harmfulness of the presence of foreign bodies in the digestive tract.

**Keywords:** Magnetic beads, digestive tract foreign body, perforation

## INTRODUCTION

Obstruction or perforation caused by foreign bodies in the digestive tract is one of the common acute abdominal diseases in clinic, which is more common in children (1). The ingestion of magnets accounts for approximately 1.97% of foreign bodies in the digestive tract; 80%–90% of foreign bodies in the stomach can discharge by itself, whereas merely approximately 1% of cases need surgical treatment (2). If a patient mistakenly eats several magnets, the magnets would attract each other in the gastrointestinal tract, leading to gastrointestinal tract wall compression, hypoxic necrosis, perforation, intestinal obstruction, fistula formation, and even intestinal volvulus, further leading to toxic shock. Because of the slow and hidden course of the disease, delayed diagnosis and treatment can threaten a patient's life, leading to catastrophic consequences (3, 4). This study reports the clinical data of multiple intestinal perforation or gastrointestinal obstruction caused by the mistaken ingestion of multiple magnetic beads and reviews the relevant literatures to explore the best treatment.

## MATERIALS AND METHODS

### General Information

This study was conducted in accordance with the declaration of Helsinki and was approved by the Hospital Medical Ethics Committee. An informed consent was provided by the parents of the children.

From July 2007 to February 2019, 88 patients with gastrointestinal foreign bodies were admitted to our hospital. Among these patients, 24 patients were admitted owing to multiple gastrointestinal perforation or gastrointestinal obstruction caused by mistaken ingestion of multiple magnetic beads. The age of this group of patients ranged within 1–11 years, with an average age of  $3.5 \pm 1.7$  years, and the number of magnetic beads ranged within 2–40. The children ingested the magnetic beads from two sources: 10 cases were from families, whereas 14 cases were from kindergartens or primary schools. Routine abdominal radiograph and B-ultrasound were performed in the Outpatient and Emergency Departments for diagno-

Corresponding Author: Wei-Ping Zhang; wpz999\_dr@163.com

Received: August 9, 2019 Accepted: January 28, 2020

© Copyright 2020 by The Turkish Society of Gastroenterology · Available online at [turkjgastroenterol.org](http://turkjgastroenterol.org)

DOI: 10.5152/tjg.2020.19600

sis, and a preoperative blood routine examination (white blood cell [WBC] count and C-reactive protein [CRP]) was performed after admission. These 24 patients were divided into two groups on the basis of whether an intestinal tube and/or gastric perforation was found during the operation: perforation group (n=16, 11 males and 5 females) and non-perforation group (n=8, 6 males and 2 females). In addition, the patient's symptoms, perforation site or foreign body persistence, number of foreign bodies, intraoperative location and number of foreign bodies found in those locations, intraoperative confirmation of perforation, and other specific data were collected.

### Clinical Treatment

After the clinical diagnosis, patients were given active preoperative preparation, were forbidden to eat and drink water, were given gastrointestinal decompression, and were given static anti-inflammatory treatment, according to the situation. If the B-mode ultrasonography and abdominal position film indicated that the magnetic bead foreign body was solely located in the stomach, gastroscopic exploration was the first choice. If the B-mode ultrasonography and abdominal orthostatic film indicated that the magnetic bead foreign body was located in the duodenum, small intestine, or colon; indicated that the magnetic bead foreign body was dispersed in the stomach, duodenum, small intestine, or colon; or clearly indicated gastrointestinal perforation by the magnetic bead foreign body, laparotomy would be considered.


### Statistical Analysis

The Statistical Package for the Social Sciences (SPSS) 21.0 (IBM Corp.; Armonk, NY, USA) statistical software package was used for the statistical analysis, which included the descriptive statistical analysis of the counts and percentages. Chi-square test and Fisher's exact test were performed to classify the variables, where the frequency was presented in percentage. All reported p-val-

**Table 1.** Comparison of age, gender, history, number of magnetic beads and WBC count between the perforated group and non-perforated group.

Index	Perforated group (n=16)	Non-perforation group (n=8)	p
Age	4.2±2.8	4.2±3.2	0.622
Gender			1.000
Male	11	6	
Female	5	2	
Medical history (days)	8.1±8.6	7.3±7.7	0.936
Number of magnetic beads	11.3±10.2	8.1±7.5	0.457
WBC (*10 <sup>9</sup> )	11.4±3.1	8.3±2.2	0.228
CRP (mg/L)	28.0±29.5	8.0±0.0	0.009

WBC: white blood cell; CRP: count and C-reactive protein.



**Figure 1.** Location and percentage of foreign bodies of magnetic beads (number).

ues were double-tailed, and multiple Logistic regression was performed.  $p < 0.05$  was considered to be statistically significant.

### RESULTS

Among the 24 patients admitted to our hospital because of mistaken ingestion of multiple magnetic beads, abdominal pain and vomiting were the main symptoms, accounting for 67% of the cases, followed by asymptomatic presentation (15%). The clinical symptoms of patients included abdominal pain (14 patients), vomiting (8 patients), fever (2 patients), crying (3 patients), nausea and cough (1 patient), and no symptoms (5 patients). One patient developed nausea and cough because two magnetic beads were located in the esophagus.

### MAIN POINTS

- Obstruction or perforation caused by foreign bodies in the digestive tract is one of the common acute abdominal diseases in clinic.
- This study aimed to analyze the data of 24 cases of multiple perforation or obstruction of the digestive tract caused by accidental ingestion of magnetic beads.
- This study offers diagnosis and treatment methods for the perforation or obstruction of the digestive tract caused by accidental ingestion of magnetic beads and raises the awareness regarding the harmfulness of the presence of foreign bodies in the digestive tract.

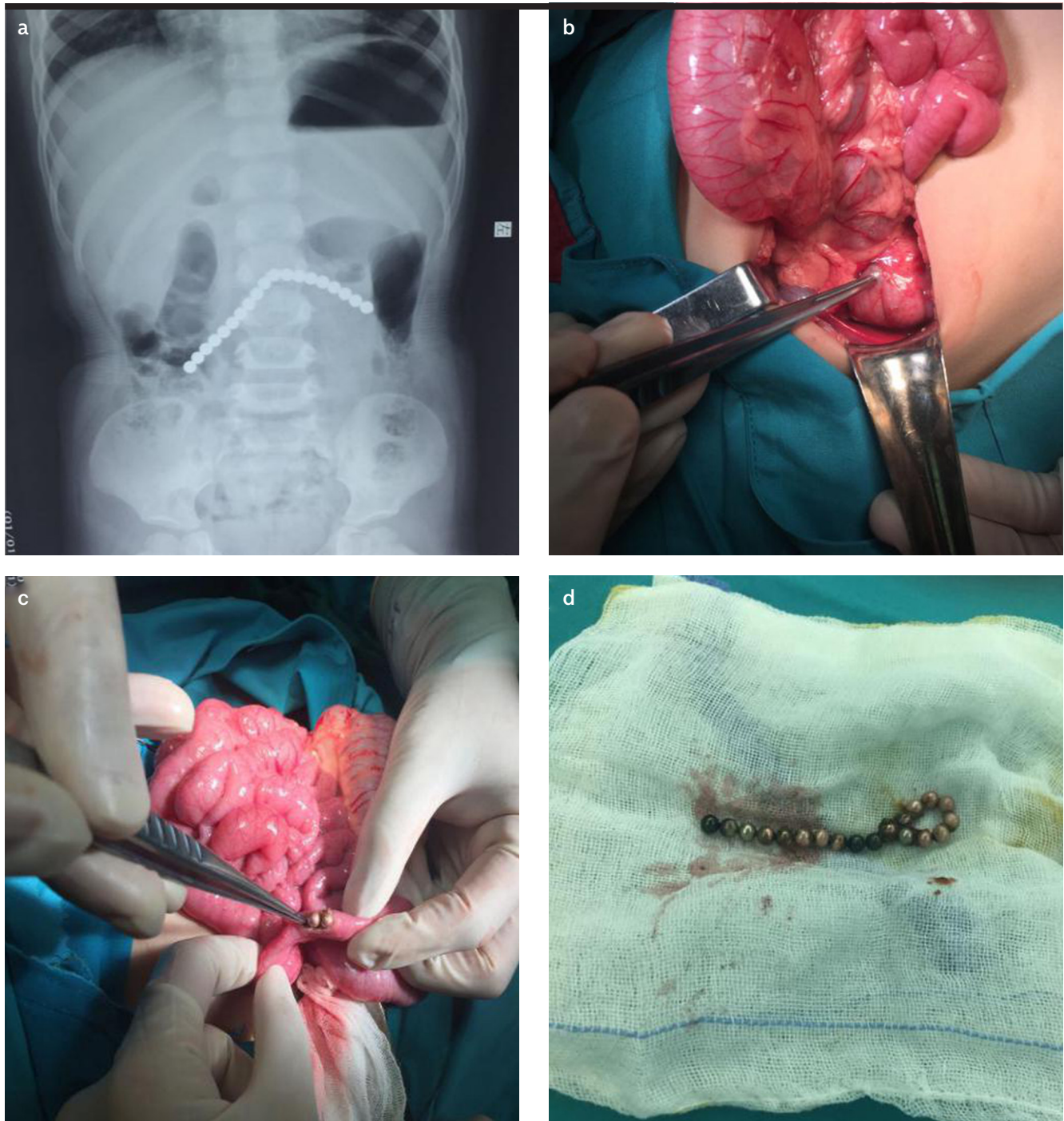
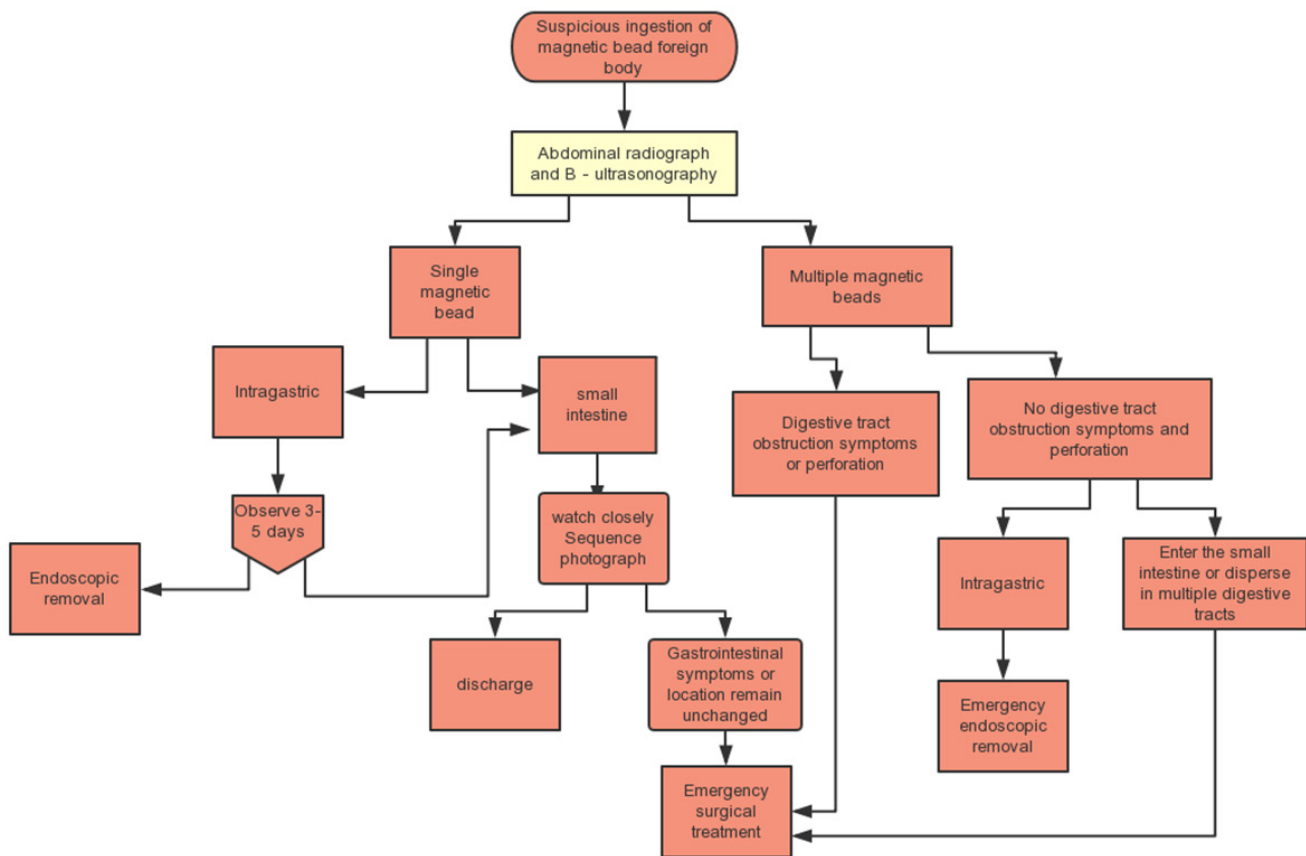


Figure 2. a-d. Location and percentage of foreign bodies of magnetic beads (number).

There was no significant difference in age, gender, history, number of magnetic beads, and WBC count between the perforated group and non-perforated group ( $p>0.05$ ), but

there was a significant difference in CRP ( $p=0.009$ ). The values were significantly higher in the perforated group than in the non-perforated group (Table 1).



**Figure 3.** The National Children's Medical Center and Beijing Children's Hospital Affiliated to Capital Medical University have formulated procedures for the diagnosis and treatment of accidental ingestion of magnetic beads.

Exploratory laparotomy and perforation repair, including intestinal perforation repair and gastric wall perforation repair, are the main operative methods, accounting for 70% of the methods. Other operative methods contain enterolysis (7%), gastroscopic extraction (14%), and gastroscopic extraction combined with laparotomy (5%). All cases recovered successfully after the surgical treatment, and no complications were found during the follow-up.

A total of 246 magnetic bead foreign bodies were found in this study. The location of these foreign bodies was mainly in the jejunum and ileum (56%), which was also the predilection site for perforation (Figures 1 and 2).

**DISCUSSION**

Foreign body ingestion remains as the common cause of emergency and surgical intervention in pediatric populations. Among all foreign bodies swallowed by children, the

proportion of accidental ingestion of magnets is very low. However, a large number of ingested magnets can cause serious injury (5). Although magnet ingestion remains rare, data from the national electronic injury monitoring system still reports the intake of more than 22,000 magnets in pediatric patients in the United States between 2002 and 2011 (6). In recent years, children's ingestion of magnets has exhibited a significantly increasing trend (7). A survey data in North America revealed that in the past 10 years, the number of cases that require surgery for ingesting magnets is twice that for all cases in the past (8).

Tsai et al. (9) revealed that when NdFeB (Neodymium Iron Boron) magnets were close to each other (3.5-4.6 cm), they attracted each other. Hence, magnets that entered the abdominal cavity attracted each other across the intestinal wall. Othman (10) reported a case of multiple bowel perforation secondary to the ingestion of magnetic beads in a 3-year-old patient. They recommend-



ed immediate surgical referral for early assessment and appropriate intervention. Pogorelić et al. (11) reported a case of intestinal obstruction and fistula formation after the ingestion of 25 magnets in a 2 year-old-girl. They recommended that single magnet ingestion should be treated as a non-magnetic foreign body, whereas multiple magnet ingestion should be closely monitored, and a surgical approach would be the best option to prevent or cure the complications caused by the multiple magnets. Cox et al. (12) found in their experiment that once magnets become attracted to each other, intestinal tissues get sandwiched in the middle, and these magnets do not separate by themselves, which might lead to rapid necrosis and perforation of the intestinal tubes. According to this study, early abdominal B-mode ultrasonography and Abdominal radiographs should be performed to confirm the diagnosis. Active measures should be taken for cases with high CRP before an operation.

Once the magnetic beads enter the body, these would affect the blood supply of the gastric or intestinal wall, leading to local mucosal ischemia and necrosis or even perforation, which can only be removed by surgery. After eating the magnetic beads, the early symptoms of children are atypical, and a child's ability to express is limited. It is usually impossible to accurately state the history of eating, which makes early diagnosis difficult. Therefore, clinicians should be fully aware of the dangers of eating a magnet. It is necessary to be vigilant when encountering suspicious cases of ingestion of magnets, when carefully inquiring the medical history, and when carefully examining the body and the parallel abdominal positive and lateral radiographs, to determine the number and location of magnetic beads (3). If the intake of a single magnet can be determined and the size of the magnet is less than 5 cm (13), this intake can only be managed by observation. However, in most cases, interventions are needed when multiple magnets are ingested or when the actual number cannot be determined. If the object remains in the stomach or esophagus, it should be removed by endoscopy, when possible. Once multiple magnets pass through the pylorus, laparoscopic or laparotomy operations are needed to avoid further complications, and the number of multiple magnets should be closely observed. Once magnet attraction is detected, immediate exploration should be performed (14). At present, there is no unified guide and consensus for the accidental ingestion of magnets (magnetic beads). On the basis of the previous guidelines and algorithms and the Shanghai Children's Hospital's magnet foreign body treatment process, the National Children's

Hospital Science Center and Beijing Children's Hospital Affiliated to Capital Medical University developed the diagnosis and treatment processes of magnetic beads (2, 15, 16,) (Figure 3).

The surgical methods include laparotomy or laparoscopic exploration. If the patient is in a critical condition or the abdominal distension is obvious, laparotomy should be the first choice. If conditions permit, laparoscopic exploration may be considered. Regardless of whether laparotomy or laparoscopic exploration is performed, the approximate position of the magnetic beads can be determined by preoperative B-mode ultrasound and abdominal supine position film. Intraoperative forceps (hemostatic forceps or manipulative forceps) can be used near the magnetic beads to feel the suction, and these can be removed through perforated intestinal tubes. The digestive tract (from stomach to rectum) must be explored during the operation to ensure that no digestive tract perforation is missed. Before closing the abdomen, it should be ensured that all magnetic bead foreign bodies are removed (3). Owing to the number of accidental ingestions, which has caused serious harm to children, many countries have legislated to ban magnetic beads. However, in China, magnetic beads can still be easily purchased. Parental supervision is a key factor in injury prevention. Warning labels are ineffective in publicizing the dangers of high-power magnets to the public. Improving the implementation of existing standards and public health legislation would be indispensable for mitigating these serious and even fatal injuries.

In conclusion, early symptoms of mistaken ingestion of multiple magnetic beads in children are often atypical but may lead to catastrophic consequences. Early abdominal B-mode ultrasonography and abdominal positioning filming should be performed to confirm the diagnosis. Active measures should be taken immediately for cases with high CRP before an operation. At the same time, this calls on the society and relevant officials to control the production and sale of magnetic beads.

## REFERENCES

1. Cheng W, Tam PK. Foreign-body ingestion in children: experience with 1265 cases. *J Pediatr Surg* 1999; 34: 1472-6. [\[Crossref\]](#)
2. Digestive Endoscopic Branch of Chinese Medical Association. Expert consensus on the endoscopic treatment of foreign bodies in the upper gastrointestinal tract in China (2015, Shanghai). *Chin J Digest End* 2016; 33: 19-28.
3. Sun J, Xu WY, Lv ZB, Huang Q, Wu YB, Sheng QF. Multiple magnetic foreign bodies in gastrointestinal tract: 3 cases report and literature review. *Chinese Journal of Practical Pediatrics* 2016; 31: 1339-42.

4. Baierlein SA. Magnet ingestion. *Dtsch Arztebl Int* 2013; 110: 298. [\[Crossref\]](#)
5. Waters AM, Teitelbaum DH, Thorne Vivian, Bousvaros A, Noel RA, Beierle EA. Surgical management and morbidity of pediatric magnet ingestions. *J Surg Res* 2015; 199: 137-40. [\[Crossref\]](#)
6. Silverman JA, Brown JC, Willis MM, Ebel BE. Increase in pediatric magnet-related foreign bodies requiring emergency care. *Ann Emerg Med* 2013; 62: 604. [\[Crossref\]](#)
7. Naji H, Isacson D, Svensson JF, Wester T. Bowel injuries caused by ingestion of multiple magnets in children: a growing hazard. *Pediatr Surg Int* 2012; 28: 367-74. [\[Crossref\]](#)
8. Bousvaros A, Bonta C, Gilger M, Noel RA. Advocating for child health: how the North American Society for Pediatric Gastroenterology, Hepatology, and Nutrition took action against high-powered magnets. *J Pediatr* 2014; 164: 4-5. [\[Crossref\]](#)
9. Tsai J, Shaul DB, Sydorak RM, Lau ST, Akmal Y, Rodriguez K. Ingestion of magnetic toys: report of serious complications requiring surgical intervention and a Proposed management algorithm. *Penn J* 2013; 17: 11-4. [\[Crossref\]](#)
10. Othman MY, Srihari S. Multiple magnet ingestion: The attractive hazard. *Med J Malaysia* 2016; 71: 211-2.
11. Pogorelić Z, Borić M, Markić J, Jukić M, Grandić L. A Case of 2-Year-Old Child with Entero-Enteric Fistula Following Ingestion of 25 Magnets. *Acta Medica (Hradec Kralove)* 2016; 59: 140-2. [\[Crossref\]](#)
12. Cox S, Brown R, Millar A, Numanoglu A, Alexander A, Theron A. The risks of gastrointestinal injury due to ingested magnetic beads. *S Afr Med J* 2014; 104: 277-8. [\[Crossref\]](#)
13. Bendig DW. Removal of blunt esophageal foreign bodies by flexible endoscopy without general anesthesia. *Am J Dis Child* 1986; 140: 789-90. [\[Crossref\]](#)
14. Vijaysadan V, Perez M, Kuo D. Revisiting swallowed troubles: intestinal complications caused by two magnets: a case report, review and proposed revision to the algorithm for the management of foreign body ingestion. *J Am Board Fam Med* 2006; 19: 511-6. [\[Crossref\]](#)
15. Hussain SZ, Bousvaros A, Gilger M, et al. Management of ingested magnets in children. *J Pediatr Gastroenterol Nutr* 2012; 55: 239-42. [\[Crossref\]](#)
16. Waters AM, Teitelbaum DH, Thorne V, Bousvaros A, Noel RA, Beierle EA. Surgical management and morbidity of pediatric magnet ingestions. *J Surg Res* 2015; 199: 137-40. [\[Crossref\]](#)