







# A simplified technique of esophageal self-expandable metallic stent placement without fluoroscopic and endoscopic guidance for treating esophageal carcinoma

Ratnakar Kini , Sabarinathan Ramanathan , Pugazhendhi Thangavel , Premkumar Karunakaran , Kani Shaik Mohamed , Murali Ananthavadivelu 

Department of Medical Gastroenterology, Madras Medical College and Rajiv Gandhi Government General Hospital, Tamil Nadu, India

**Cite this article as:** Kini R, Ramanathan S, Thangavel P, Karunakaran P, Mohamed KS, Ananthavadivelu M. A simplified technique of esophageal self-expandable metallic stent placement without fluoroscopic and endoscopic guidance for treating esophageal carcinoma. *Turk J Gastroenterol* 2018; 29: 80-6.

## ABSTRACT

**Background/Aims:** Self-expandable metallic stent (SEMS) placement with fluoroscopic guidance is a commonly used technique to relieve obstruction in patients with esophageal carcinoma. However, it has disadvantages such as radiation exposure. SEMS placement with endoscopic guidance also has the disadvantages of causing discomfort to patients as the endoscope and SEMS assembly are simultaneously used and it needs two experts for the procedure to be performed. To overcome these disadvantages, a simplified technique for SEMS placement was developed that does not require fluoroscopic or endoscopic guidance. Our objective was to compare the efficacy and safety of this simplified technique with the conventional SEMS placement method.

**Materials and Methods:** This is a retrospective study including patients with esophageal carcinoma who underwent SEMS placement for the palliation of dysphagia.

**Results:** Sixty-two patients were placed on stents for the palliation for esophageal carcinoma, with 46 patients in the conventional technique group (group A) and 16 in the simplified technique group (group B). The duration of the procedure was considerably lesser in group B than in group A (2 min 53 s vs. 15 min 4 s,  $p=0.001$ ). The technical success rate achieved in groups A and B were 97.82% and 100%, respectively. SEMS placement required two experts in the conventional technique whereas the simplified technique required only one expert.

**Conclusion:** The advantages of the simplified technique are as follows: technical ease, cost-effectiveness, no exposure to radiation, requirement of minimal manpower, and less time-consuming; these advantages make it the technique day-care procedure.

**Keywords:** Self-expandable metallic stent, esophageal carcinoma, fluoroscopy, dysphagia, simplified technique

## INTRODUCTION

Esophageal cancer is the eighth most common cancer among all cancers worldwide, with a substantially increasing prevalence. More than 50% of patients present with either locally advanced disease or metastasis at the time of diagnosis (1). Self-expandable metallic stent (SEMS) placement is imperative in the amelioration of dysphagia, thereby enhancing the quality of life of patients (1). Furthermore, the use of SEMSs is explicitly associated with relatively lower morbidity and mortality rates than the use of plastic stents (2).

Earlier studies had evinced that SEMS placement is performed under fluoroscopic or endoscopic guidance. However, the limited accessibility to fluoroscopy and the haz-

ard of radiation exposure are established as the two main pitfalls pertaining to fluoroscopic guidance (3). Although endoscopic guidance during SEMS placement is an effort to overcome these limitations, it had a constraint of affecting patient compliance during the procedure, thereby demanding the use of a nasogastroscope or an ultra-thin scope (4). The other disadvantage is that it requires two experts to perform the procedure. The first expert is needed to place the SEMS, and the second expert performs endoscopy and assists the first expert to place the stent under endoscopic guidance. Therefore, we developed a simplified technique of SEMS placement without fluoroscopic guidance and with limited endoscopic guidance i.e., endoscopy was used only to assess the extent of the carcinoma of esophagus and not during the stent

ORCID IDs of the authors: R.K.0000-0002-0421-5960; S.R. 0000-0002-6292-7341; P.T. 0000-0003-3562-0130; P.K. 0000-0002-7711-9478; K.M. 0000-0001-9732-3612; M.A. 0000-0002-1499-8911

Address for Correspondence: Ratnakar Kini E-mail: [gastrokini@gmail.com](mailto:gastrokini@gmail.com)

Received: June 8, 2017 Accepted: September 11, 2017

© Copyright 2018 by The Turkish Society of Gastroenterology · Available online at [www.turkjgastroenterol.org](http://www.turkjgastroenterol.org)

DOI: 10.5152/tjg.2018.17112

deployment. In this study, we compared the safety and efficacy of the simplified technique of esophageal SEMS placement (without fluoroscopic guidance) with that of the conventional method (with fluoroscopic guidance) in patients with advanced esophageal carcinoma.

### **MATERIALS AND METHODS**

This retrospective study was conducted with prior institutional ethics committee approval. The endoscopy registry and inpatient case records of patients who were diagnosed of advanced esophageal carcinoma and who underwent SEMS placement between January 2012 and September 2016 were analyzed. Telephone calls were made to collect data whenever necessary. During this study period, all patients in who underwent SEMS placement were divided into two groups on depending on whether fluoroscopic guidance was performed. Patients who were aged over 18 years and with histopathologically proven carcinoma of the esophagus not amenable to curative treatment were included. Patients with tumors located 2-3 cm close to the cricopharyngeus muscle and who required the placement of more than one stent or telescopic SEMS were excluded. Pre-procedural informed consent was obtained from the patients.

Data pertaining to the early and late complications of stent placement were obtained from the case records. Complications were defined as early and late based on those occurring before SEMS placement and 7 days after SEMS placement (5).

Dysphagia scoring was done before and after the procedure:

- Grade 0: no dysphagia, able to tolerate normal food
- Grade 1: able to swallow most foods
- Grade 2: able to swallow a soft diet
- Grade 3: able to swallow liquid only
- Grade 4: unable to swallow saliva

Technical success was defined as the ability to accurately place and expand the stent at the desired level in the first attempt.

### **Technique**

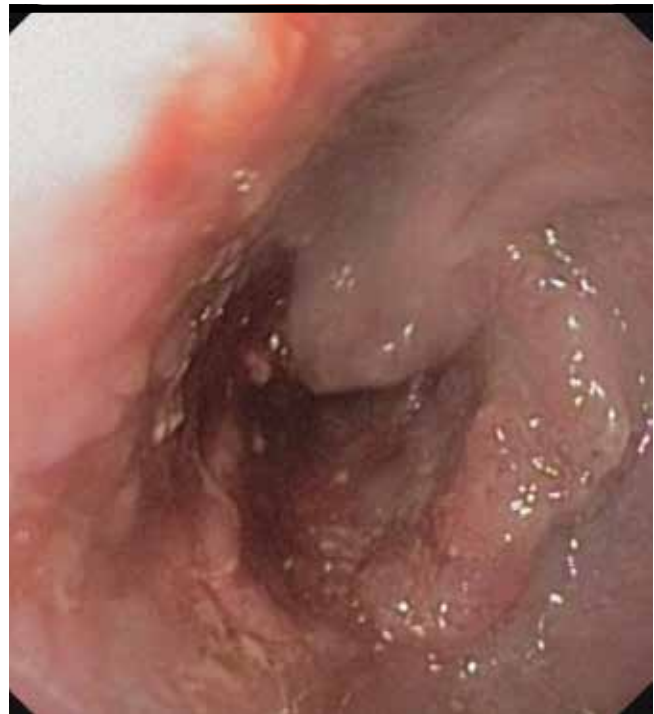#### **Conventional technique (with fluoroscopic guidance)-group A**

Under conscious sedation with intravenous midazolam and fentanyl, esophagogastroduodenoscopy (EGD) was

performed to compute the proximal and distal extents of the lesion. Whenever dilatation was needed, a guide wire (0.035 inch with a soft tip) was placed across carcinoma of esophagus and it was dilated with serial Savary-Gilliard bougies. The proximal and distal extents of the tumor were marked under fluoroscopic guidance either by an external radiopaque marker or by the submucosal injection of a contrast material serving as an internal marker. The guide wire was lodged in the antrum of the stomach, further after withdrawal of the endoscope the SEMS assembly would be threaded over the guide wire. The SEMS was placed by the distal release technique. During and after placement, the proper positioning of the SEMS was firmly established fluoroscopically and the expansion of the SEMS was endoscopically confirmed on the next day of the procedure.

#### **Simplified technique (without fluoroscopic or endoscopic guidance)-group B**

With conscious sedation, EGD was performed to determine the anatomical level of the esophagogastric junction and proximal and distal extents of the lesion as well as to locate the cricopharynx. The proximal extent of the carcinoma of esophagus (Figure 1) was noted



**Figure 1.** Endoscopic view of the upper level of carcinoma of esophagus [In this case, it was noted at 24 cm (X)]




Figure 2. The level of 22 cm (X-2) noted on the stent assembly indicated by a red arrow

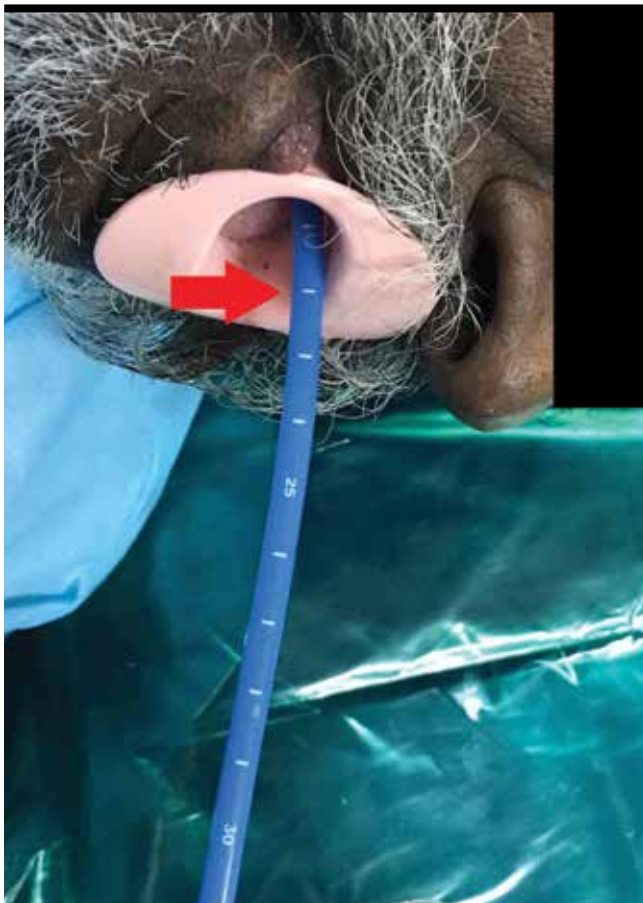


Figure 3. The stent assembly threaded over the guide wire till the 22-cm mark on the stent assembly reaches the incisor teeth (red arrow)

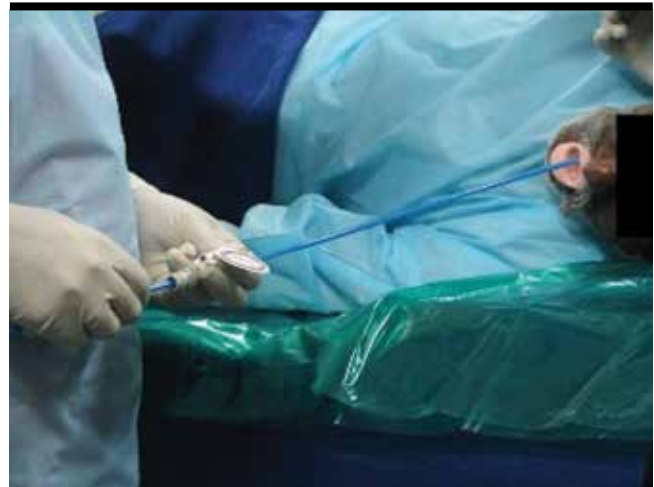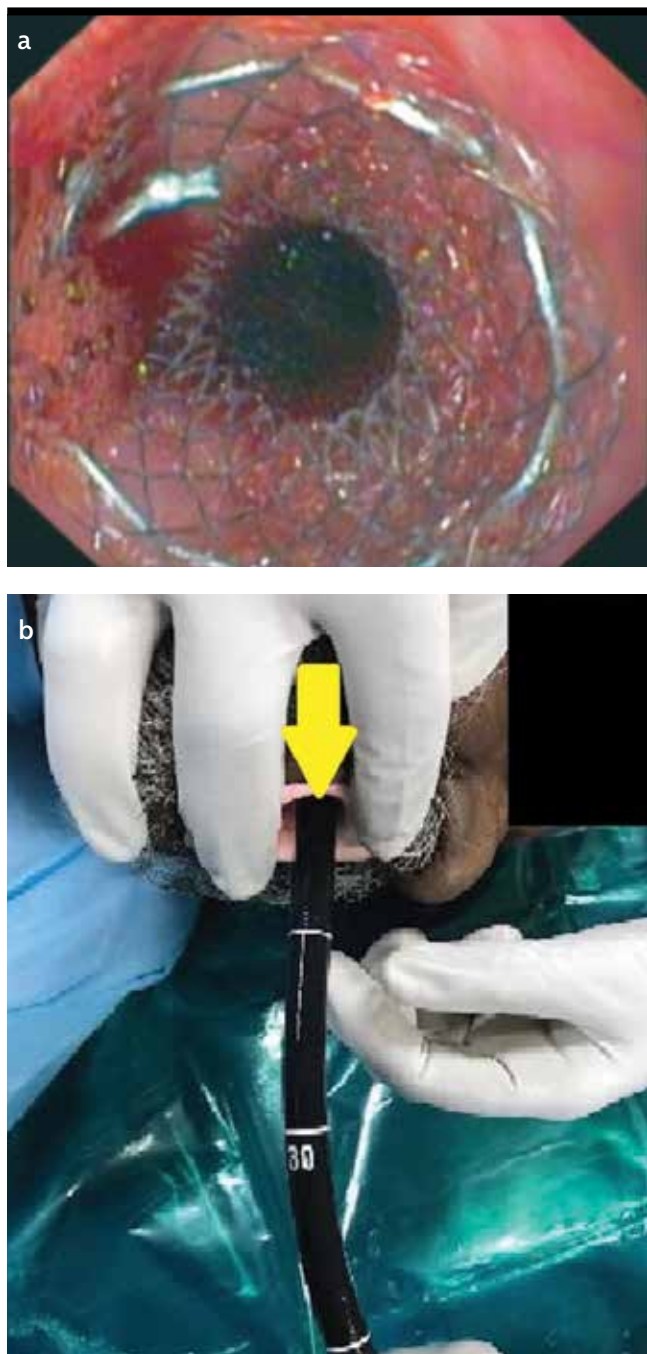


Figure 4. The 22-cm mark on the stent assembly was kept at the incisor teeth. Stent placement was done slowly using the distal release technique

in centimeters from the incisor teeth (X). The proximal end of the stent was planned to be placed at least 2 cm above this level (X-2). Factor (X-2) is to account for the expanded portion of the SEMS. This level (X-2) was noted over the graduation visualized in the inner sheath of the stent assembly seen through the transparent outer sheath (Figure 2). The stent assembly was then threaded over the guide wire till the (X-2) mark on the stent assembly reached the incisor teeth (Figure 3). At this point, the marking on the stent assembly (X-2) at the incisor teeth was the same as the distance at which the proximal extent of the stent was planned to be placed. After confirming this, stent placement was slowly performing using the distal release technique (Figure 4). Post-procedure endoscopy was performed to affirm the position of the proximal end of SEMS (Figure 5a,b). After SEMS placement, the patients were placed in the semi-recumbent position and kept nil orally and the infusion of clear oral fluids was started 6 h later. The following day, a soft semi-solid diet was initiated according to the tolerance of the patient.

#### Statistical analysis

Statistical analysis was performed using (IBM Inc.; SPSS Statistics for Windows, Version 24.0. Armonk, NY, ABD) The independent samples t-test and paired t-test were used to compare patients between the two groups and within the groups, respectively. The Mann-Whitney U test was performed for quantitative variables.  $p < 0.05$  was considered as the level of significance.



**Figure 5. a, b.** (a) Endoscopic appearance of the esophageal SEMS after placement (b) The proximal end of the SEMS at 22 cm of the esophagus from the incisors as confirmed by the marking on the endoscope (yellow arrow)

**RESULTS**

A total of 62 patients were placed on stents for the palliation for esophageal carcinoma, with 46 patients in group A and 16 in group B. The demographic findings and char-

**Table 1.** Demographic characteristics and features of the patients

Variable	With fluoroscopic guidance (n=46)	Without fluoroscopic guidance (n=16)	p
Age (years)	58.8±11.7	56.6±13.3	0.535
Sex, n (%)			
Male	33 (71.74%)	13 (81.25%)	0.458
Female	13 (28.26%)	3 (18.75%)	
Tumor site, n (%)			
Upper esophagus	7 (15.22%)	3 (18.75%)	0.743
Mid-esophagus	30 (65.22%)	11 (68.75%)	0.799
Lower esophagus	9 (19.56%)	2 (12.5%)	0.527
Tracheoesophageal fistula, n (%)	13 (28.26%)	3 (18.75%)	0.458
Lesion extent (cm)	8.4±2.8	7.5±2.1	0.274
Type of carcinoma, n (%)			
Squamous cell carcinoma	41 (89.13%)	14 (87.5%)	0.860
Adenocarcinoma	4 (8.7%)	2 (12.5%)	0.660
Undifferentiated	1 (2.17%)	0 (0%)	0.555

acteristics of the patients are shown in Table 1. The mean age of the patients was 57.7±12.5 y. There was no statistically significant difference in the age of the patients in the two groups (p=0.535). Of the 62 patients included in the study, 46 were male and 16 were female. In groups A and B, the most common site of the tumor was mid-esophagus, as observed in about 65.22% and 68.75% of the patients, respectively. The existence of tracheoesophageal fistula was observed in about 16 patients. The extent of the lesion was about 8.4±2.8 cm and 7.5±2.1 cm in groups A and B, respectively, and was almost homogenous in both the groups (p=0.274). Considering the type of carcinoma, squamous cell carcinoma was the most common histopathological type observed in both study groups. Dysphagia was evaluated before and after the procedure with the dysphagia score. The dysphagia score was not significantly different between the groups (Table 2). There was a statistically significant difference within the groups (p= 0.001 in both groups) before and after SEMS placement, suggesting a greater degree of improvement in dysphagia in both groups. The mean duration of the procedure was 15 min 4 s in group A and 2 min 53 s in group B; this difference

**Table 2.** Outcomes and results

Variable	With fluoroscopic guidance (n=46)	Without fluoroscopic guidance (n=16)	p
<b>Dysphagia score</b>			
Before	2.8±0.58	3±0.63	0.453
After	0.39±0.57	0.43±0.62	0.798
Mean procedure duration	15 min 4s	2 min 53sec	0.001
Technical success rate	97.82%	100%	0.555
No. of experts (main+ assistant) involved	1+1	1+0	

**Table 3.** Post-procedure complications

Variable	With fluoroscopic guidance (n=46)	Without fluoroscopic guidance (n=16)	p
<b>Immediate complications</b>			
<b>SEMS repositioning</b>			
Stent removal	12 (26.08%)	0 (0%)	0 (0%)
Perforation	1 (2.17%)	1 (6.25%)	0 (0%)
Aspiration	0 (0%)	0 (0%)	0.096
Delivery system entrapment	2 (4.35%)	0 (0%)	0.555
Procedure-related mortality	0 (0%)	0 (0%)	0.400
<b>Early complications (≤7 days)</b>			
Chest pain	14 (30.43%)	4 (25%)	0.682
Nausea and vomiting	9 (19.56%)	3 (18.75%)	0.944
Upper gastrointestinal bleeding	1 (2.17%)	0 (0%)	0.555
<b>Late complications (&gt;7 days)</b>			
Gastroesophageal reflux	6 (14.28%)	3 (20%)	0.606
Tumor outgrowth	10 (23.80%)	4 (26.67%)	0.827
Migration	2 (4.76%)	0 (0%)	0.394
Bleeding	0 (0%)	0 (0%)	
Food impaction	4 (9.52%)	1 (6.67%)	0.739
Lost to follow-up	4	1	

was statistically significant (p=0.001), suggesting the superiority of the simplified technique over the conventional technique. The technical success rate achieved in groups

A and B were 97.82% and 100%, respectively. The conventional technique needed two experts for SEMS placement, whereas the simplified technique needed only one expert. With regard to immediate complications, 26.08% and 6.25% of the patients in groups A and B, respectively, underwent SEMS repositioning due to distal migration. In group A, two patients developed aspiration and one patient underwent stent removal due to lodging of the SEMS in the cricopharynx during repositioning. Both complications were not seen in group B. Other immediate complications such as perforation, delivery system entrapment, and procedure-related mortality were not present in both groups. Early complications (≤7 days) and late complications (>7 days) observed in the study groups were similar, with no statistically significant difference between them (Table 3). The patients were followed up at the end of one week and every month thereafter. Four patients in group A and one patient in group B were lost to follow-up.

**DISCUSSION**

Esophageal SEMS placement is extremely efficacious in the palliation of dysphagia due to carcinoma of esophagus (6). SEMS placement has advantages of being technically compliant and brings about the immediate relief of symptoms, resulting in it becoming the treatment of choice in patients with unresectable esophageal carcinoma, including those complicated by fistulas (7). SEMS is slightly better than rigid plastic stents in the palliation of dysphagia (8), thereby significantly improving the quality of life of patients (9,10).

SEMS placement with fluoroscopic guidance has the disadvantage of the non-feasibility of using the fluoroscopic system in hospitals with limited settings in developing countries (11, 12). Occasionally, it also causes problems such as the migration of an external marker on movement, dissolution of the contrast agent used as an internal marker, and more importantly, hazardous radiation exposure. To overcome these issues, another technique is sought that necessitates the use of endoscopy alone for SEMS placement and its safety and efficacy is comparable to fluoroscopic guidance (2,13-20). There are few studies stating that the individual use of endoscopy is not feasible in patients with upper esophageal carcinoma and those with tight strictures. It also inconveniences patients due to insertion of an endoscope and the stent assembly, thereby requiring the use of ultra-thin or slim endoscopy (3,12). Considering this, we developed a simplified technique that could be safely performed in settings where

**Table 4.** Comparison between various methods of esophageal SEMS placement

S.No.		Under fluoroscopic guidance	Under endoscopic guidance	Simplified technique
1.	Fluoroscopy	Needed	Not needed	Not needed
2.	Exposure to radiation	Present	Absent	Absent
3.	Placement of external/internal marker	Required	Not required	Not required
4.	Number of experts needed	Two	Two	One
5.	Simultaneous use of stent assembly and endoscopy	No	Yes	No
6.	Duration of the procedure	Long	Short	Very short
7.	Patient comfort	Good	Not good	Good

fluoroscopic guidance and ultra-thin endoscopy are lacking. This technique is applicable only for stents that have external ruler markings used for measuring and judging stent placement.

In our simplified technique group, fully covered Niti-S™ Esophageal stent (outer diameter, 18 mm and length, 15 cm; Taewoong Medical Co.) was placed in 15 patients, and a fully covered Ottomed™ Bravo esophageal stent (outer diameter, 18 mm and length, 14 cm; Mitra Medical Services) was placed in 1 patient. Stents with outer diameters of 18 and 22 mm and lengths of 10 to 16 cm that were either partially or fully covered such as NITI-S, Ultraflex, or Endotechnik, based on the availability, were used in the conventional group in our study.

This study compared stent placement with or without fluoroscopic guidance in a single institution and used patients of similar demographics and characteristics. Both groups exhibited a comparable statistical significant improvement in dysphagia. Immediate, early, and late complications were homogenous between the groups, revealing that both techniques are equally safe.

The main advantage of the simplified technique is the reduction in procedure duration compared with that in the conventional method (2 min 53 s vs. 15 min 4 s). This study also shows that the simplified technique is highly efficacious in terms of its technical success rate (100%). The other advantages that increase the value of the simplified technique are as follows: technical ease, cost-effectiveness, and no hazardous radiation exposure; therefore, this technique can be used as a day-care procedure.

The additional advantage is that it requires only one expert to advance the stent assembly, thereby minimizing manpower; the conventional technique requires two experts: one for fixing the markers and operating the fluoroscope and the other for advancing the stent assembly. In the method used for stent placement under only endoscopic guidance, two experts are needed: one to handle the endoscope and the other to place the stent. Through-the-scope stents are also available (Tae Woong Medical); they serve the purpose of no radiation use and single operator delivery. Table 4 shows a comparison between various techniques of esophageal SEMS placement.

Some limitations of this study are as follows: retrospective nature of the study and smaller sample size in the simplified technique group. Further prospective studies in a larger population would add value in terms of the safety and efficacy of the simplified technique of SEMS placement. Stents in the simplified technique are all fully covered, whereas those in the conventional technique have various stent diameters and lengths and are also covered and uncovered; thus, a head-to-head comparison and outcomes measures cannot be made with surety.

After reviewing the literature, we found that there were no data available till date regarding SEMS placement using the simplified technique. We invented this new method of SEMS placement, which is simple, safe, effective, precise, requires minimal manpower, is less time-consuming, and without radiation exposure. Hence, we propose that this simplified method would have a promising role in SEMS placement in the future after more comprehensive evaluations in a larger series.

**Ethics Committee Approval:** Ethics committee approval was received for this study from institutional ethics committee of Madras Medical College (Decision Date: 02.08.2016/Decision No: 05082016)

**Informed Consent:** Written informed consent was obtained from patients who participated in this study.

**Peer-review:** Externally peer-reviewed.

**Author contributions:** Concept - R.K.; Design - R.K., S.R., P.T.; Supervision - R.K., P.T., M.A.; Resource - R.K., P.K., K.M.; Materials - R.K., P.K., K.M.; Data Collection and/or Processing - R.K., S.R.; Analysis and/or Interpretation - R.K., S.R., P.K.; Literature Search - R.K., R.S., K.M.; Writing - R.K., R.S.; Critical Reviews - P.T., M.A., P.K.

**Acknowledgements:** The authors sincerely thank all patients for their participation in this study, the nursing staff of Institute of Medical Gastroenterology of Madras Medical College and Rajiv Gandhi Government General Hospital for their support and Dr. Breetha Sabarinathan and Dr. Amudhan Aravind towards preparing this manuscript.

**Conflict of Interest:** No conflict of interest was declared by the authors.

**Financial Disclosure:** The authors declared that this study has received no financial support.

## REFERENCES

1. Spaander MC, Baron TH, Siersema PD, et al. Esophageal stenting for benign and malignant disease: European Society of Gastrointestinal Endoscopy (ESGE) Clinical Guideline. *Endoscopy* 2016; 48: 939-48.
2. Khara HS, Diehl DL, Gross SA. Esophageal stent fracture: Case report and review of the literature. *World J Gastroenterol* 2014; 20: 2715-20.
3. Ferreira F, Bastos P, Ribeiro A, et al. A comparative study between fluoroscopic and endoscopic guidance in palliative esophageal stent placement. *Dis Esophagus* 2012; 25: 608-13.
4. Siddiqui AA, Ansari S, Ghouri MA, Memon MS. Self expandable metallic stent endoscopic insertion in esophageal cancer. *J Coll Physicians Surg Pak* 2010; 20: 502-5.
5. Wilkes EA, Jackson LM, Cole AT, Freeman JG, Goddard AF. Insertion of expandable metallic stents in esophageal cancer without fluoroscopy is safe and effective: a 5-year experience. *Gastrointest Endosc* 2007; 65: 923-9.

6. Reijm AN, Didden P, Bruno MJ, Spaander MC. Early pain detection and management after esophageal metal stent placement in incurable cancer patients : A prospective observational cohort study. *Endosc Int Open* 2016; 890-4.
7. Constantinescu G, Şandru V, Ilie M, Nedelcu C, Tincu R, Popa B. Treatment of Malignant Esophageal Fistulas : Fluoroscopic Placement of Esophageal SEMS, Endoscopically-assisted through Surgical Gastrostomy . A Case Report. *J Gastrointest Liver Dis* 2016; 25: 249-52.
8. Nasa M, Sharma ZD, Choudhary NS, Puri R, Sud R. Removable self-expanding metal stents insertion for the treatment of perforations and postoperative leaks of the esophagus. *Indian J Gastroenterol* 2016; 35:101-5.
9. McCarty TR, Njei B. Self-expanding metal stents for acute refractory esophageal variceal bleeding: A systematic review and meta-analysis. *Dig Endosc* 2016; 28: 539-47.
10. Sisman G, Baran B. Placement of a self-expanding metal stent to treat esophagogastric benign anastomotic stricture via retroflexed ultrathin endoscopy: A case report with a video. *Clin Endosc* 2015; 48: 428-30.
11. White RE, Chepkwony R, Mwachiro M, Burgert SL, Enders FT, Topazian M. Randomized Trial of Small-diameter Versus Large-diameter Esophageal Stents for Palliation of Malignant Esophageal Obstruction. *J Clin Gastroenterol* 2015; 49: 660-5.
12. Karakoy M, Gultepe E, Pandey S, Khashab MA, Gracias DH. Silane surface modification for improved bioadhesion of esophageal stents. *Appl Surf Sci* 2014; 311: 684-9.
13. Gangloff A, Lecleire S, Di Fiore A, et al. Fully versus partially covered self-expandable metal stents in benign esophageal strictures. *Dis Esophagus* 2015; 28: 678-83.
14. Dua KS, Latif SU, Yang JF, Fang TC, Khan A, Oh Y. Efficacy and safety of a new fully covered self-expandable non-foreshortening metal esophageal stent. *Gastrointest Endosc* 2015; 80: 577-85.
15. Almadi MA, Bamihriz F, Aljebreen AM. Fatal aorto-esophageal fistula bleeding after stenting for a leak post sleeve gastrectomy. *World J Gastrointest Surg* 2013; 5: 337-40.
16. Maetani I, Shigoka H, Omuta S, Gon K, Saito M. What is the preferred shape for an esophageal stent flange? *Dig Endosc* 2012; 24: 401-6.
17. Hamai Y, Hihara J, Manabu E, Okita R, Shimizu K, Okada M. Successful management of multiple esophago-respiratory fistulas using two types of stent: Report of a case. *Surg Today* 2011; 41: 560-2.
18. Gouveris HT, Mann WJ, Lippert BM. Successful rigid endoscopic removal of a esophageal subtotally covered nitinol stent 11 months after initial placement. *Eur Arch Otorhinolaryngol* 2009; 266: 927-31.
19. Maneglia V, Ben Soussan E, Savoye G, et al. Multidetector CT in patients with esophageal stent as a palliative treatment for stenosing esophageal cancer: a feasibility study. *Scand J Gastroenterol* 2007; 42: 1339-46.
20. Baron TH, Burgart LJ, Pochron NL. An internally covered (lined) self-expanding metal esophageal stent: tissue response in a porcine model. *Gastrointest Endosc* 2006; 64: 263-7.