


# A rare cause of multiple small bowel ulcers and strictures in a 10-year-old child

Teera Kijmassuwan<sup>1</sup>, Pornthep Tanpowpong<sup>1</sup> , Sani Molagool<sup>2</sup>, Suporn Treepongkaruna<sup>1</sup>

<sup>1</sup>Division of Gastroenterology, Department of Pediatrics, Mahidol University School of Medicine, Ramathibodi Hospital, Bangkok, Thailand

<sup>2</sup>Department of Surgery, Mahidol University School of Medicine, Ramathibodi Hospital, Bangkok, Thailand

**Cite this article as:** Kijmassuwan T, Tanpowpong P, Molagool S, Treepongkaruna S. A rare cause of multiple small bowel ulcers and strictures in a 10-year-old child. *Turk J Gastroenterol* 2018; 29: 110-13.

## ABSTRACT

Enteritis and small bowel ulcers can be caused by inflammatory bowel disease, drug-induced enteritis, cytomegalovirus, tuberculosis, or intestinal lymphoma. Cryptogenic multifocal ulcerous stenosing enteritis (CMUSE) is an uncommon idiopathic cause of ulceration and stricture of the small bowel. CMUSE can occur in adults, but only few pediatric cases have been reported. Inflammatory bowel disease and other causes should be carefully sought first before the diagnosis of CMUSE can be made. Previous reports demonstrated that surgical intervention may be necessary for both diagnostic and therapeutic purposes. With regard to the management, systemic corticosteroids may help, and surgery plays a role in patients present with signs of intestinal obstruction. We report a young girl who presented with a prolonged history of refractory iron deficiency anemia with protein-losing enteropathy without other obvious gastrointestinal symptoms. She underwent several laboratory and endoscopic investigations as well as histopathology of the resected full-thickness small bowel area before a proposed diagnosis of CMUSE was made. A trial of immunosuppression (both prednisolone and azathioprine) was initiated that provided a relatively satisfactory result.

**Keywords:** Anemia, enteroscopy, idiopathic, laparotomy, protein-losing

## INTRODUCTION

Small bowel ulcers and strictures in children are commonly caused by inflammatory bowel disease (IBD), non-steroidal anti-inflammatory drugs (NSAIDs)-associated enteritis, cytomegalovirus-related gastrointestinal (GI) disease, tuberculous enteritis, and intestinal lymphoma. Most of the aforementioned conditions usually require mucosal or tissue biopsy or even tissue resection and histopathology. Differential diagnosis of other less common conditions should be considered after certain diseases have been ruled out (e.g., IBD, infection, cancer). Cryptogenic multifocal ulcerous stenosing enteritis (CMUSE) is a rare condition that has been reported in both adults and children (1). A proposed diagnosis of CMUSE can be made after excluding other diseases. Moreover, the treatment for this condition is not well-established and the prognosis also remains uncertain. Some reports also noted poor prognosis with frequent recurrence (2). We herein report a girl who had a longstanding history of iron deficiency anemia (IDA) and later was noted to have protein-losing enteropathy. Laborious investigations including surgical

resection of the stricture site aid in making a provisional diagnosis of CMUSE.

## CASE PRESENTATION

A 10-year-old girl presented with a 7-year history of refractory IDA. She denied abdominal pain, nausea or vomiting, rash, joint pain, bloody stools, constipation, or diarrhea. Her nutritional history was reportedly normal. History of drug use including NSAIDs was also denied. She had been given iron supplementation since she was 3 years old, but the iron status did not improve. At the age of 7 years, her anemia worsened. She received two red blood cell transfusions and underwent upper GI endoscopy that showed small duodenal ulcer. Histopathology showed organizing ulcer without *Helicobacter pylori*. When she was 8 years old, her anemia again worsened. Endoscopic and histologic examinations of the repeated upper GI endoscopy and colonoscopy were also normal. The iron supplementation was continued in conjunction with a proton pump inhibitor. Almost a year later, she was referred to our institution with refractory IDA.

ORCID ID of the authors: P. T. 0000-0002-3246-8009.

Address for Correspondence: Pornthep Tanpowpong E-mail: [pornthep.tan@mahidol.ac.th](mailto:pornthep.tan@mahidol.ac.th)

Received: August 22, 2017 Accepted: September 7, 2017

© Copyright 2018 by The Turkish Society of Gastroenterology · Available online at [www.turkjgastroenterol.org](http://www.turkjgastroenterol.org)

DOI: 10.5152/tjg.2018.17232

Her past medical history was significant for rupture appendicitis and underwent appendectomy. No demonstrable history of GI problems in the family or close contact to cases with tuberculosis. Besides iron supplementation and acid blockade, no other drug use was noted. Body weight and height were both at the 10<sup>th</sup> percentiles. She was noted to have pale conjunctivae but other examinations were unremarkable without signs of extraintestinal presentation of IBD. There were no red or white blood cell in the microscopic stool examination or urinalysis, but stool Guaiac test was positive in three occasions. The initial laboratory investigations were the following: white blood cells 7.920/mm<sup>3</sup> (N 46%, L 47%, E 4%), hemoglobin 8 g/dL with MCV 68 fL, and platelet count 599.000/mm<sup>3</sup> with transferrin saturation 2.8% (normal: >16) compatible with IDA. Liver transaminases were within normal limits, but hypoalbuminemia (serum protein 42 g/L, serum albumin 18.3 g/L) was documented. Urine protein was negative. Spot stool for alpha-1 antitrypsin was high at 37.3 mg/dL (normal: <5). Erythrocyte sedimentation rate and C-reactive protein were both within the normal range. Another repeated upper GI endoscopy and colonoscopy (third endoscopy) was normal, and histopathology showed no signs of IBD or infection. Purified protein derivative skin test, stool acid fast bacilli, and small intestinal tissue biopsy for tuberculosis polymerase chain reaction (PCR) were all negative.

The upper GI and small bowel follow-through contrast study showed no definite evidence of abnormal bowel dilatation or obstruction. Subsequently, being able to define possible mucosal lesions in the small bowel, video capsule enteroscopy was performed (Figure 1), which demonstrated a single ulcer in the proximal jejunum and few circumferential ulcerations causing strictures and bleeding in the mid-to-distal small bowel. Unfortunately, the capsule retained in the small bowel. Retrograde double balloon enteroscopy was performed to remove the capsule. Enteroscopy showed the following: (i) diffuse swelling and inflammation just above the ileocecal valve (ICV); (ii) two 0.5-1.5 cm, 1/4-1/2 circumferential ulcers were seen at 30-40 cm above ICV; and (iii) a tight stricture site 50 cm from the ICV. Contrast study through the enteroscopy showed pre-stenotic dilatation, few stricture sites, and a capsule 10 cm proximal to the tight stricture. Again, histopathology of the terminal ileum showed reactive lymphoid follicle without picture of IBD, drug-related ileitis, or specific infection. The patient remained asymptomatic.

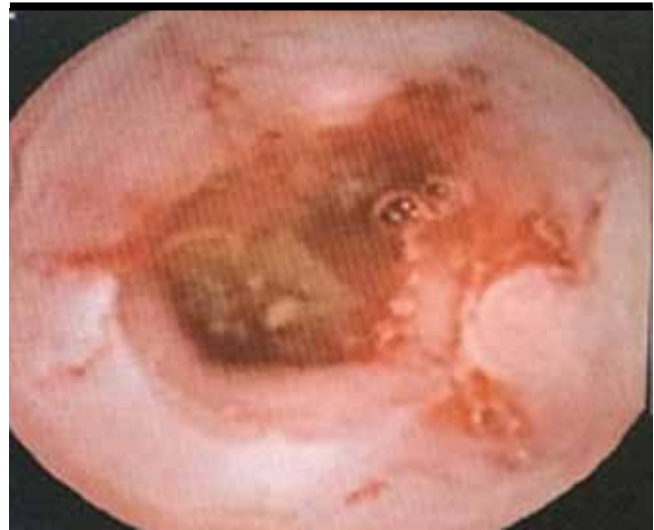

Figure 1. Video capsule enteroscopy showed a single ulcer in the proximal jejunum

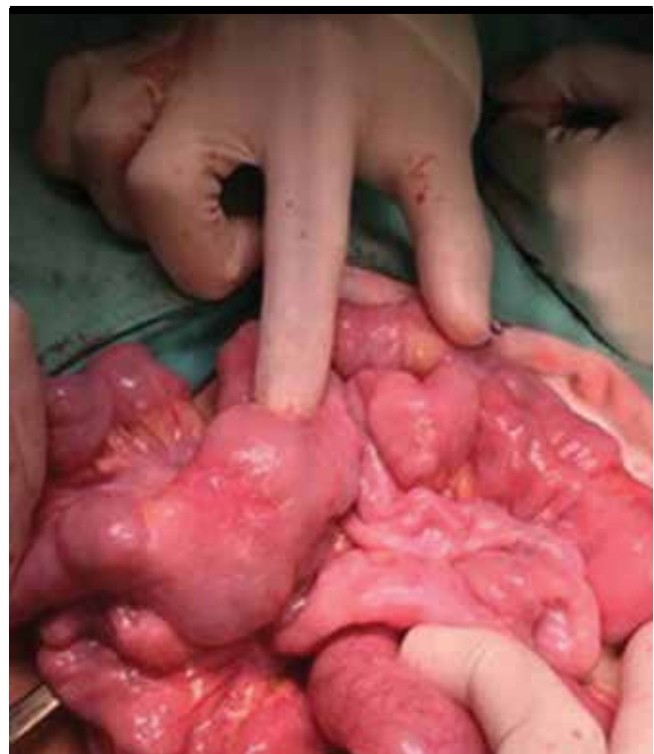

Figure 2. Dilated intestinal wall and scar were found in the small bowel. Multiple out-pouching lesions, swelling, and inflammatory spots were found along the ileum 45 cm up from the capsule-stricture point

The pediatric surgery team was then consulted for capsule removal. The initial plan was to try reducing inflammation and swelling with systemic corticosteroids (prednisolone 2 mg/kg/day), which may lead to capsule expulsion. However, after 3 weeks of prednisolone, plain

radiograph confirmed capsule retention. Therefore, exploratory laparotomy was performed. The capsule retained at 50 cm from the ICV. Small intestinal wall was dilated proximal to the stricture site with small intraluminal ulcers and scar. Multiple out-pouching lesions, swelling, and inflammatory spots were also found 45 cm up from the stricture site. Segmental ileal resection (about 7 cm in length) with end-to-end anastomosis was performed (Figure 2). Histopathology revealed acute ulcerative inflammation without picture of IBD or infection. At this time, a presumptive diagnosis was CMUSE, according to the clinical diagnostic criteria.

Systemic corticosteroid was again resumed at 2 mg/kg/day. Anemia and hypoalbuminemia improved after 6 weeks (hemoglobin 10.2 g/dL and albumin 23.8 g/L). The side effects of systemic corticosteroid were not observed. Then, the steroid was weaned, and azathioprine was initiated at 1 mg/kg/day as a steroid-sparing agent. After following for 10 months, hemoglobin and albumin increased to 13.2 and 34 g/L, respectively. The spot stool for alpha-1 antitrypsin decreased to 8.3 mg/dL. Magnetic resonance enterography was performed and still demonstrated a focal narrowing of the terminal ileum associated with mild contrast enhancement of the bowel wall, suggestive of mild inflammatory process. No evidence of obstruction, fistula, or abscess formation. She remained asymptomatic with a weight gain of 5 kilograms in 10 months, with a low dose of corticosteroid and azathioprine.

We obtained an informed consent from the patient's caregiver.

## DISCUSSION

Cryptogenic multifocal ulcerous stenosing enteritis is a rare idiopathic cause of ulceration and stricture of small bowel, which can be presented with acute or chronic GI bleeding, symptoms of bowel obstruction, abdominal pain, anemia, hypoalbuminemia, and perforation (1-5). Most aforementioned studies demonstrated case series of patients with CMUSE, which were mainly diagnosed during adulthood and only few were diagnosed before the age of 10 years. Etiology and pathogenesis is still unknown and poorly understood but may be related with X-link recessive reticulate pigmentary disorder, heterozygosity of the cytoplasmic phospholipase A2-a gene (3), and mutation of *SLOCO2A1* gene (6,7). Characteristics of small intestinal lesions can be defined by radiologic

investigations such as contrast study, macroscopic examination via capsule or balloon enteroscopy, or surgical specimens.

Differential diagnoses of CMUSE include IBD especially Crohn's disease, NSAIDs-associated enteritis, intestinal lymphoma, or infectious enteritis such as cytomegalovirus or tuberculosis. Location of lesion, clinical symptoms, and radiographic findings can be similar between IBD and CMUSE, but IBD usually has a histopathological picture of "chronicity" on intestinal biopsy. Extraintestinal manifestations are usually seen in IBD, but not in CMUSE (8). Matsumoto et al. (5) reported that 81% of the reported cases during the second to third decades of life had longstanding anemia similar to our patient, and 9 of 15 cases had symptoms for >10 years before a final diagnosis was made by abnormal small bowel findings. More recent studies also reported a long period of time between the symptom onset to the proposed diagnosis (2,3). Our reported patient started having IDA without obvious GI symptoms since the case was 3 years old and was diagnosed with CMUSE at the age of 10 years.

To our knowledge, there is no specific guideline for treating this condition. Systemic corticosteroids may help but most patients develop corticosteroid dependent (1). Chung et al. (2) found a response rate of corticosteroid was approximately 25%. To be able to wean corticosteroid, we attempted to use azathioprine as a maintenance immunomodulator that is frequently used in IBD. Surgical treatment has been reported to have a role in patients with suspected CMUSE with a sign of bowel obstruction or if the diagnosis remains uncertain. Prognosis also remains uncertain due to a paucity of evidence in children. The recurrence rate of disease was reportedly high even after surgery or corticosteroid treatment among adults (2,4).

**Informed Consent:** Informed consent was obtained from patient's caregiver who participated in this study.

**Peer-review:** Externally peer-reviewed.

**Author contributions:** Concept - T.K., P.T., S.T.; Supervision - P.T.; Materials - S.M.; Data Collection and/or Processing - P.T., T.K., S.T.; Literature Search - T.K., P.T.; Writing - T.K., P.T.; Critical Reviews - T.K., P.T., S.M., S.T.

**Conflict of Interest:** No conflict of interest was declared by the authors.

**Financial Disclosure:** The authors declared that this study has received no financial support.

## REFERENCES

1. Kohoutová D, Bártořová J, Tachecí I, et al. Cryptogenic multifocal ulcerous stenosing enteritis: a review of the literature. *Gastroenterol Res Pract* 2013; 2013: 918031.
2. Chung SH, Park SU, Cheon JH, et al. Clinical characteristic and treatment outcomes of cryptogenic multifocal ulcerous stenosing enteritis in Korea *Dig Dis Sci* 2015; 60: 2740-5.
3. Esaki M, Umeno J, Kitazono T, Matsumoto T. Clinicopathologic features of chronic nonspecific multiple ulcers of small intestine. *Clin J Gastroenterol* 2015; 8: 57-62.
4. Perlemuter G, Guillevin L, Legman P, Weiss L, Couturier D, Chaussade S. Cryptogenic multifocal ulcerous stenosing enteritis: an atypical type of vasculitis or a disease mimicking vasculitis. *Gut* 2001; 48: 333-8.
5. Matsumoto T, Iida M, Matsui T, Yao T. Chronic nonspecific multiple ulcers of the small intestine: a proposal of the entity from Japanese gastroenterologists to Western enteroscopists. *Gastrointest Endosc* 2007; 66: 99-107.
6. Uchida K, Nakajima A, Ushijima K, et al. Pediatric onset chronic nonspecific multiple ulcers of small intestine: a nationwide survey and genetic study in Japan. *J Pediatr Gastroenterol Nutr* 2017; 64: 565-8.
7. Umeno J, Hisamatsu T, Esaki M, et al. A hereditary enteropathy caused by mutations in the *SLCO2A1* gene, encoding a prostaglandin transporter. *PLoS Genet* 2015; 11: 1005581.
8. Freeman HJ. Small intestinal multifocal stenosing ulceration. *Dig Dis Sci* 2015; 60: 2568-70.