



“Double band” technique for intractable or recurrent esophageal variceal hemorrhage: An alternative rescue method

Cite this article as: Akar T. “Double band” technique for intractable or recurrent esophageal variceal hemorrhage: an alternative rescue method. Turk J Gastroenterol 2017. DOI: 10.5152/tjg.2017.17337

Dear Editor,

Acute esophageal variceal bleeding is a serious medical emergency and may have very high rates of mortality and morbidity, particularly in patients with end-stage liver disease associated with intractable variceal hemorrhage. Early recurrent bleeding (within 5 days) can be observed in nearly 8%-20% of patients with cirrhosis and is associated with a high risk for death, particularly in patients with a high hepatic venous pressure gradient and fibrotic varix caused by previously repeated banding (1). For such patients, when bleeding control fails, a rescue therapy is often required and recommended (2). However, the current rescue methods such as self-expandable esophageal covered metal stent, transjugular intrahepatic portosystemic shunt, and shunt surgery are so expensive and complex that cannot be performed in every unit or they are also associated with additional mortalities such as encephalopathy, esophageal necrosis, or perforation (2). Consequently, attempting an alternative endoscopic intervention before suggesting any of the abovementioned complex rescue therapies may be a more appropriate approach. Herein, we describe a salvage rescue method called “double band” technique in a patient with cirrhosis and recurrent and intractable esophageal bleeding that arises from the fibrotic varix caused by previously repeated banding.

A 40-year-old man with cirrhosis who had massive, recurrent, and intractable esophageal bleeding was admitted to our hospital. The patient was in a state of shock, with a high heart rate (150 rpm/min) and hemoglobin level of 6.1 g/dL (normal range, 12-15 g/dL). After resuscitation, endoscopic examination revealed an actively bleeding point arising from a large-sized esophageal varix at 5 cm above the gastroesophageal junction (Figure 1). Initially, four endoscopic variceal bands were carefully applied between

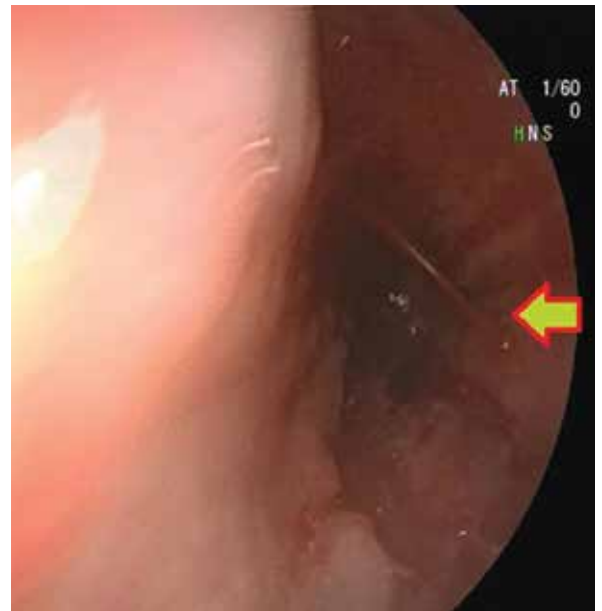


Figure 1. Endoscopic view of an actively bleeding point arising from the fibrotic varix (arrow)

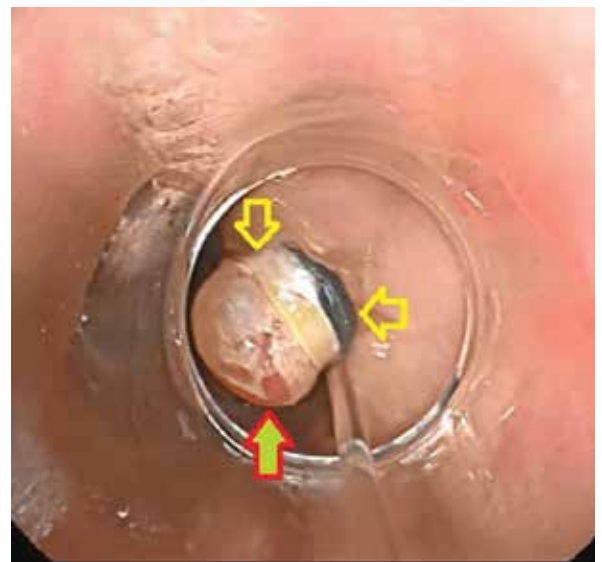


Figure 2. The use of the “double band” technique for the bleeding site of the fibrotic varix (two same color arrows shows two bands at the baseline of the varix, and another arrow shows the bleeding site)

the gastroesophageal junction and bleeding site. Despite recurrent attempts, the single band did not stably stay on the bleeding site and fell into the lumen, probably owing to tissue stiffening caused by previous banding applications or high volume blood flow. Hence, we performed "double band" technique using single suction and placing two bands at the baseline of the bleeding site of varix. Finally, it was observed that the double band was stably fixed on there and the bleeding stopped (Figure 2).

According to guideline recommendations for intractable or recurrent esophageal hemorrhage, there is no clear explanation regarding this issue, such as how many times can endoscopy be repeated and which endoscopic salvage technique should be performed before invasive rescue therapy is initiated (1-3). All recommended rescue therapies have complex properties and a higher mortality and morbidity rate than endoscopic variceal banding (2,4). Therefore, we used the "double band" technique for our patient based on our previous experience. With respect to our experience, we performed this technique for seven patients with cirrhosis and intractable or recurrent variceal bleeding during second-time endoscopic procedure, and our success rate was 100%. No patient underwent rescue therapy, and no further bleeding was observed after the procedure.

In conclusion, during endoscopy, if there is a bleeding site is observed on the varix with a high risk for recurrent or intractable hemorrhage, the technique of "double band application to bleeding point" can be safely implanted as an efficient and easy-to-perform rescue method.

Informed Consent: Written informed consent was obtained from the patient who participated in this study.

Peer-review: Externally peer-reviewed.

Conflict of Interest: No conflict of interest was declared by the author.

Financial Disclosure: The author declared that this study has received no financial support.

Tarik Akar

Department of Gastroenterology, Bülent Ecevit University School of Medicine, Zonguldak, Turkey

REFERENCES

1. Garcia-Tsao G, Sanyal AJ, Grace ND, et al. Prevention and management of gastroesophageal varices and variceal hemorrhage in cirrhosis. *Hepatology* 2007; 46: 922-38. [CrossRef]
2. Tripathi D, Stanley AJ, Hayes PC, et al. U.K. guidelines on the management of variceal haemorrhage in cirrhotic patients. *Gut* 2015; 64: 1680-704. [CrossRef]
3. Garbuzenko DV. Current approaches to the management of patients with liver cirrhosis who have acute esophageal variceal bleeding. *Curr Med Res Opin* 2016; 32: 467-75. [CrossRef]
4. Robles-Medrandá C, Puga-Tejada M, Ospina J, Valero M, Pitanga Lukashok H. Over-the-scope clip in the management of fibrotic esophageal variceal bleeding (with video). *Gastrointest Endosc* 2017 Apr 29. doi: 10.1016/j.gie.2017.04.027. [Epub ahead of print][CrossRef]

Address for Correspondence: Tarik Akar

E-mail: drtarikakar@gmail.com

Received: June 1, 2017

Accepted: June 13, 2017

Available Online Date: September 19, 2017

© Copyright 2017 by The Turkish Society of Gastroenterology • Available online at www.turkjgastroenterol.org • DOI: 10.5152/tjg.2017.17337