



## A rare cause of gastric outlet obstruction

Nurettin Suna, Serkan Öcal, Diğdem Özer Etik, Haldun Selçuk, Fatih Hilmioğlu, Sedat Boyacıoğlu

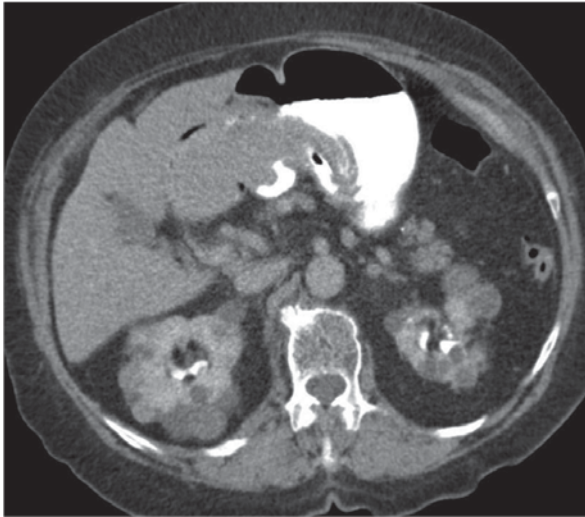
Department of Gastroenterology, Başkent University School of Medicine, Ankara, Turkey

Cite this article as: Suna N, Öcal S, Etik DÖ, Selçuk H, Hilmioğlu F, Boyacıoğlu S. A rare cause of gastric outlet obstruction. Turk J Gastroenterol 2017. DOI: 10.5152/tjg.2017.17183

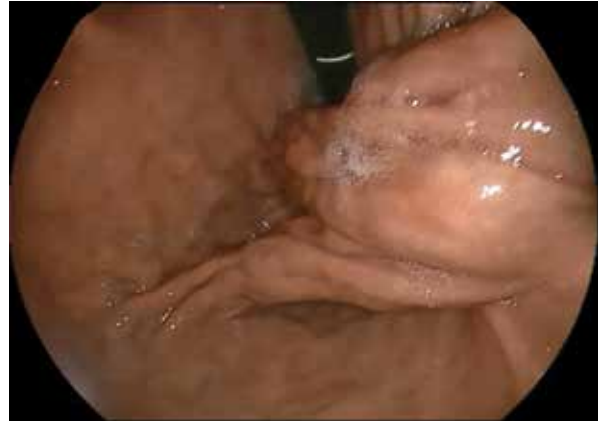### Question:

An 89-year-old woman was admitted with complaints of nausea, vomiting, and epigastric pain after having meals. A computed tomography scan of the abdomen showed a 12.5-cm mass in the fundus of the stomach, which extended to the duodenum (Figure 1).

Upper gastrointestinal endoscopy showed a polypoid lesion with a thick and long stalk that originated from fundus and extended to the duodenum. The head of the lesion prolapsed through the pylorus into the duodenal bulb and caused gastric outlet obstruction (Figure 2).



**Figure 1.** A computed tomography scan of the abdomen showed a giant mass that was 12.5 cm in length in the fundus of the stomach, which extended to the duodenum



**Figure 2.** Upper gastrointestinal endoscopy showed a polypoid lesion with a thick and long stalk that originated from the fundus and extended to the duodenum

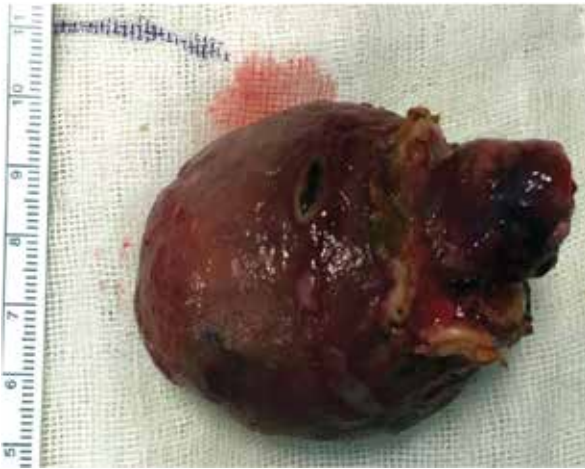**Address for Correspondence:** Nurettin Suna E-mail: nurettinsuna.44@hotmail.com

**Received:** March 27, 2017

**Accepted:** April 26, 2017

**Available Online Date:** 13.07.2017

© Copyright 2017 by The Turkish Society of Gastroenterology • Available online at [www.turkjgastroenterol.org](http://www.turkjgastroenterol.org) • DOI: 10.5152/tjg.2017.17183



**Figure 3.** Laparoscopic wedge resection was performed for the complete removal of the giant polyp (7.5×6.5×5.5 cm at the macroscopic examination)

### Answer: Combined right and left bile duct variations

Laparoscopic wedge resection with a 1-cm rim of normal gastric tissue was performed for the complete removal of the polyp. At a macroscopic examination, it was found to be a 7.5×6.5×5.5 cm lesion (Figure 3). Its histopathology was consistent with the features of a gastrointestinal stromal tumor (GIST) with negative tumor margins. GISTs can originate from anywhere along the gastrointestinal tract, but they are frequently located in the stomach (1). Gastric GISTs are generally incidentally found during upper gastrointestinal endoscopy (2). The vast majority of gastric GISTs are asymptomatic, unless the tumor is large enough to cause symptoms or has bleeding ulcerations (2). Hyperplastic and pedunculated large gastric polyps located in the gastric antrum may cause gastric outlet syndrome (3). Although GISTs are submucosal lesions, in our case, it mimicked a pedunculated polyp. This presentation is rare for

gastric GISTs. The endoscopic appearance of the lesion was not typical for a gastric GIST. The other interesting presentation of the tumor was its long pseudo-peduncle, which caused duodenal obstruction.

**Ethics Committee Approval:** Ethics committee approval was received for this study from the ethics committee of Başkent University School of Medicine (Decision No: 162-4765).

**Informed Consent:** Written informed consent was obtained from the patient who participated in this study.

**Peer-review:** Externally peer-reviewed.

**Author contributions:** Concept - N.S., S.Ö., H.S.; Design - D.Ö.E., F.H., S.Ö.; Supervision - A.S.B., F.H., D.Ö.E.; Resource - N.S., S.Ö., F.H.; Materials - N.S., D.Ö.E., S.Ö.; Data Collection and/or Processing - D.Ö.E., S.Ö., N.S.; Analysis and/or Interpretation - F.H., H.S., S.Ö.; Literature Search - N.S., D.Ö.E., F.H.; Writing - N.S., F.H., H.S.; Critical Reviews - A.S.B., F.H., H.S.

**Conflict of Interest:** No conflict of interest was declared by the authors.

**Financial Disclosure:** The authors declared that this study has received no financial support.

### REFERENCES

1. Koo DH, Ryu MH, Kim KM, et al. Asian Consensus Guidelines for the Diagnosis and Management of Gastrointestinal Stromal Tumor. *Cancer Res Treat* 2016; 48: 1155-66. [\[CrossRef\]](#)
2. Quek R, George S. Gastrointestinal stromal tumor: a clinical overview. *Hematol Oncol Clin North Am* 2009; 23: 69-78. [\[CrossRef\]](#)
3. Shaib YH, Ruge M, Graham DY, Genta RM. Management of gastric polyps: an endoscopy-based approach. *Clin Gastroenterol Hepatol* 2013; 11: 1374-84. [\[CrossRef\]](#)