

# Results of positive proximal margin after resection for hilar cholangiocarcinoma: An analysis of 42 cases

Volkan Öter , İltar Özer , Tahsin Dalgıç , Cemil Binarbaşı , Murat Ulaş , Erdal Birol Bostancı 

Department of Gastroenterological Surgery, Yüksek İhtisas Training and Research Hospital, Ankara, Turkey

**Cite this article as:** Öter V, Özer İ, Dalgıç T, Binarbaşı C, Ulaş M, Bostancı EB. Results of positive proximal margin after resection for hilar cholangiocarcinoma: An analysis of 42 cases. *Turk J Gastroenterol* DOI: 10.5152/tjg.2018.17752.

## ABSTRACT

**Background/Aims:** Hilar cholangiocarcinoma (HC) is a tumor that invades the confluence of the left and right hepatic bile ducts. Surgery is the definitive treatment but is also technically demanding. Here, we report our experience on 42 patients who underwent surgical resection for HC. The aim of the present study was to evaluate the margin status of resected specimens on frozen sections and the impact of R1 resection margin on survival.

**Materials and Methods:** A total of 42 patients with HC who underwent surgical resection in our clinic between January 2008 and January 2017 were included in the study. Patients' charts were evaluated retrospectively.

**Results:** The 1-, 2-, and 4-year overall survival rates of the 42 patients were 76.2%, 40%, and 10.7%, respectively. The median survival rates of the patients with negative and positive proximal surgical margins were 22 (11.93-32.06) and 17 (14.43-19.56) months, respectively. There was no statistically significant difference between these two groups.

**Conclusion:** In HC, surgery achieving negative proximal surgical margin is often very difficult. Our results demonstrate that frozen sections are reliable for the assessment of the invasion status of the proximal and distal ductal surgical margins. Although complete resection is potentially curative, survival of the patients with HC is still poor. If there is no distant metastasis at the time of diagnosis, then extirpating surgery should be encouraged as survival of the patients with positive and negative margins is not significantly different.

**Keywords:** Klatskin tumor, frozen section, positive surgical margin, survival analysis

## INTRODUCTION

Hilar cholangiocarcinoma (HC), or Klatskin tumor, is a malignant tumor that is notorious for invading the confluence of the left and right hepatic bile ducts (1). It is a rare, devastating, and highly malignant disease of the bile duct. Surgery is the mainstay approach for a chance of a cure but is technically very demanding (2,3). The standard surgical treatment for HC consists of extrahepatic bile duct resection with major hemihepatectomy, resection of the caudate lobe, and dissection of the regional lymph nodes. This approach has been found to increase resectability and to improve surgical outcomes (4,5). The major goal of surgery is R0 resection; however, this is frequently not possible for many patients with HC due to the location of these tumors and invasion into the intrahepatic biliary system. Thus, intraoperative frozen sections are performed for the assessment of the distal and proximal bile duct margins to assure a resection with negative margins (5-7). In case of a positive margin on frozen sec-

tions, further dissection should be performed if it is technically possible (5-7). Nevertheless, extensive dissection has been associated with remarkable morbidity and mortality in high volume centers (10%-15%) (8). Therefore, recent studies show that extensive resection to obtain a negative proximal bile duct margin does not provide any survival advantage. Here we report our experience in 42 patients who underwent surgical resection for HC.

The aim of the present study was to evaluate the margin status of resected specimens on frozen sections and the impact of R1 resection margin on survival.

## MATERIALS AND METHODS

### Patients and tumors

Ethics committee approval was not received due to the retrospective nature of the study. The authors declared that the research was conducted according to the prin-

ORCID IDs of the authors: V.Ö. 0000-0002-0639-1917; İ.Ö. 0000-0001-6902-0913; T.D. 0000-0003-0677-2944; C.B. 0000-0002-9300-8129; M.U. 0000-0002-3507-8647; E.B.B. 0000-0002-0663-0156.

Corresponding Author: Volkan Öter; otervolkan@gmail.com

Received: December 3, 2017 Accepted: April 16, 2018 Available online date: October 8, 2018

© Copyright 2018 by The Turkish Society of Gastroenterology · Available online at www.turkjgastroenterol.org

DOI: 10.5152/tjg.2018.17752

ciples of the World Medical Association Declaration of Helsinki "Ethical Principles for Medical Research Involving Human Subjects", (amended in October 2013). The charts of 42 patients with HC who underwent surgical resection between January 2008 and January 2017 were evaluated retrospectively. Data of the patients were obtained from a prospectively recorded database. Information included patient demographics, histopathological evaluation of the specimens, and outcomes. Proximal margin status and R0 resection rate were recorded. Early

postoperative results and survival were analyzed. Table 1 shows the demographic and clinical features.

Initial evaluation of these patients included having detailed medical history and symptoms, physical examination, laboratory findings, and cross-sectional imaging, usually with dynamic abdominal computed tomography (CT) and magnetic resonance imaging with cholangiopancreatography. CT imaging was performed to assess the potential resectability of the disease and to evaluate the possible remnant liver volume after resection.

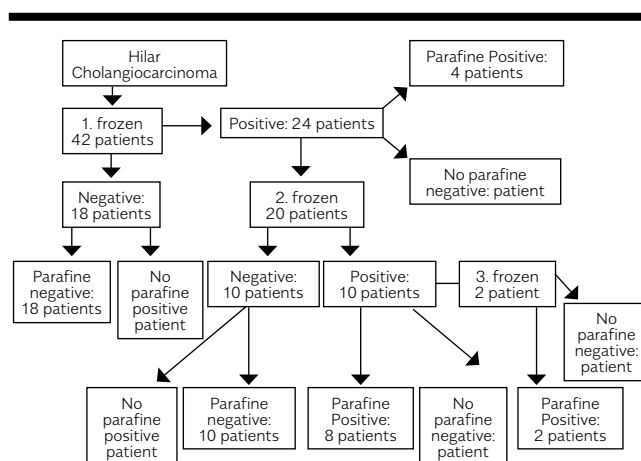
**Table 1.** Clinicopathological data of resected patients with hilar cholangiocarcinoma

Total patients	42
Age (median, range), years	62.3±7.1 (range 48-74)
Gender	
Male	28 (66,7%)
Female	14 (33,3%)
Preoperative biliary decompression	22 (52,4%)
Median follow-up for surviving patients, months	17,5 (range 4-61)
Bismuth-Corlette classification	
I	4 (9,5%)
IIIa	20 (47,6%)
IIIb	18 (42,9%)
Tumor differentiation	
Well (G1)	20 (47,6%)
Moderately (G2)	18 (42,9%)
Poorly (G3)	4(9,5%)
Primary tumor (T)	
T1	6 (14,2%)
T2a	28 (66,7%)
T2b	6 (14,2%)
T3	2 (4,7%)
Lymph node metastasis	
Absent	28 (66,7%)
Present	14 (33,3%)
American Joint Committee on Cancer staging (8 <sup>th</sup> edition, 2018)	
I	6 (14,3%)
II	22 (52,3%)
IIIC	10 (23,8%)
IVA	4 (9,5%)
Proximal resection margin	
Negative	28 (66,7%)
Positive	14 (33,3%)

The standard operation included resection of the right or left hepatectomy with en-bloc resection of the caudate lobe with hepatoduodenal lymph node dissection. The tumor extension of the bile duct was defined according to the Bismuth-Corlette classification (10). All lesions were classified as perihilar bile duct cancer. Patients with intrahepatic cholangiocarcinoma were excluded.

**Operative procedures**

Intraoperative frozen sections were performed in all patients to assess bile duct margin. When any evidence of tumor positive margin was detected, additional resection of the proximal bile duct was performed if technically possible. After frozen section analysis, all duct margins were re-evaluated on permanent slides. Margin status was classified as positive or negative margin on frozen sections. The perihilar soft tissue was thoroughly evaluated to examine radial margins and to identify positive lymph nodes. Tumor differentiation, perineural invasion, and lymphovascular invasion were also evaluated by experienced pathologists.



**Figure 1.** Diagram of frozen section diagnosis, additional resection, and fixed section diagnosis

**Statistical analysis**

SPSS version 16 software (SPSS Inc.; Chicago, IL, USA) was used for statistical analyses. For survival analyses, the Kaplan-Meier method was used. Log-rank test was used for comparison of groups. Survival was defined as the time between the initial operation and death or last follow-up.

**RESULTS**

The median age of the study group was 62.3±7.1 (48-74) years. Of the 42 patients, there were 28 (66.7%) men and 14 (33.3%) women. Of the patients, 12 (28.6%) underwent biliary decompression by percutaneous transhepatic drains, and 10 (23.8%) by endoscopic nasobiliary drainage preoperatively. Before the biliary decompression, the mean total bilirubin level was 13.06 mg/dL (min: 4.83, max: 22.38 mg/dL). The median biochemistry results at presentation of the patients in the present study were: total bilirubin 7.85 mg/dL (0.40-22.38 mg/dL) (range 0.3-1.2 mg/dL), alkaline phosphatase 416.6 IU/L (range 30-120 IU/L), carbohydrate antigen 19-9 (CA19-9) 467.5 U/mL (<37 U/mL), and carcinoembryonic antigen 2.42 mg/L (<3.8 mg/L).

The median follow-up was 17.5 (4-61) months. The anatomic extent of bile duct involvement was classified according to the Bismuth-Corlette classification (7): type I, n=4 (9.5%); type IIIa, n=20 (47.6%); and type IIIb, n=18 (42.9%). Right hepatectomy was performed in 20 (47.6%) patients, left hepatectomy in 18 (42.9%) patients, and bile duct resection without hepatectomy in 4 (9.5%) patients with R0 margin status (Table 2). Proximal R0 margin status was achieved in 28 (66.7%), and proximal R1 margin in the remaining 14 (33.3%) patients. Distal R0 margin status was achieved in all patients, and R2 resection was not encountered in any of the patients. Intraoperative frozen sections were performed to assess bile duct margin in 42 patients. A second frozen section was performed in 20 patients with positive proximal margin, and a third frozen examination was performed for only 2 patients (Figure 1).

In the postoperative period, 8 (19%) patients had wound infection, 2 (4.7%) had transient hepatic failure, 2 (4.7%) had bile fistula, and 2 (4.7%) had intra-abdominal abscess, and mortality before discharge was encountered in 1 patient who had transient hepatic failure and sepsis. The median hospital stay was 22.6 (7-180) days.

The histology of all tumors was diagnosed as adenocarcinomas. Tumors were well differentiated (G1) in 20 (47.6%) patients, moderately differentiated (G2) in 18 (42.9%), and poorly differentiated (G3) in 4 (9.5%). Of the patients, 28 (66.7%) were node negative. Of the 14 (33.3%) node positive patients, 10 (23.8%) were classified as N1, and 4 (9.5%) were classified as N2. Of the patients, 6 (14.2%) had T1 tumor, 28 (66.6%) had T2a, 6 (14.2%) had T2b, and 2 (4.76%) had T3 tumor. There were 6 (14.2%) stage I, 22 (52.3%) stage II, 10 (23.8%) stage IIIC, and 4 (9.5%) stage IVA tumors (AJCC cancer staging manual, 8th ed., New York, 2018, Springer).

The 1-, 2-, and 4-year overall survival rates of the 42 patients were 76.2%, 40%, and 10.7%, respectively. The median survival rates of the patients with negative and positive proximal surgical margins are 22 (11.93-32.06) months and 17 (14.43-19.56) months, respectively. Four patients with positive margins were still alive at the endpoint of the study with survival rates of 16, 17, 53, and 56 months. Six patients with negative margins were still alive with survival rates of 17, 18, 29, 31, 57, and 61 months. There was no statistically significant difference between these two groups (Table 3).

Table 4 shows the correlation between clinicopathological factors and survival. For univariate analysis, preoperative elevated levels of total bilirubin, male gender, and elevated CA19-9 levels (>37 U/mL) were found to be the significant predictors of poor overall survival. For multivariate analysis, only lymph node metastasis (p=0.02, 95% confidence interval 1.42-5.28) was found as an independent factor for patient survival.

**Table 2.** Operative procedures in 42 patients with hilar cholangiocarcinoma

Operative procedures	Resection margin of proximal bile duct		Total
	Negative	Positive	
Right hepatectomy and HJ	14 (%33.3)	6 (%14.3)	20 (%47.6)
Left hepatectomy and HJ	14 (%33.3)	4 (%9.5)	18 (%42.9)
Bile duct resection only and HJ	0	4 (%9.5)	4 (%9.5)
Total	28 (%66.7)	14 (%33.3)	42 (%100)

HJ: hepaticojejunostomy

**Table 3.** Postoperative data of resected patients with hilar cholangiocarcinoma

No.	Age	Gender	T	N	M	Grade	Stage (AJCC 8 <sup>th</sup> edition)	Bismuth-Corlette classification	Frozen no.	Proximal margin	Survey (months)	Dead or alive
1	58	E	II	N0	M0	I	II	3B	2	Negative	4	Dead
2	74	E	I	N0	M0	I	I	3A	2	Positive	14	Dead
3	69	E	I	N0	M0	I	I	3A	1	Negative	17	Alive
4	70	E	II	N0	M0	I	II	3A	2	Positive	17	Alive
5	71	E	II	N0	M0	II	II	1	2	Positive	14	Dead
6	54	E	II	N1	M0	II	IIIC	3B	2	Positive	17	Dead
7	60	E	II	N0	M0	I	II	3A	1	Negative	5	Dead
8	58	K	II	N0	M0	I	II	3B	1	Negative	29	Alive
9	66	E	II	N0	M0	II	II	1	3	Positive	27	Dead
10	54	E	II	N2	M0	II	IVA	3A	2	Positive	16	Dead
11	61	K	II	N0	M0	II	II	3B	1	Negative	8	Dead
12	71	E	II	N1	M0	II	IIIC	3A	2	Negative	22	Dead
13	61	E	II	N0	M0	III	II	3A	2	Negative	6	Dead
14	54	E	II	N2	M0	III	IVA	3A	2	Negative	11	Dead
15	64	E	II	N0	M0	I	II	3B	1	Negative	40	Dead
16	59	K	II	N0	M0	I	II	3A	1	Negative	61	Alive
17	61	K	III	N0	M0	II	II	3A	1	Negative	60	Dead
18	74	E	II	N1	M0	I	IIIC	3B	1	Negative	26	Dead
19	61	K	II	N0	M0	II	II	3B	2	Positive	56	Alive
20	61	K	II	N1	M0	I	IIIC	3B	2	Negative	24	Dead
21	48	K	I	N0	M0	II	I	3B	1	Negative	18	Dead
22	58	E	II	N0	M0	I	II	3B	2	Negative	5	Dead
23	74	E	I	N0	M0	I	I	3A	2	Positive	13	Dead
24	69	E	I	N0	M0	I	I	3A	1	Negative	18	Alive
25	70	E	II	N0	M0	I	II	3B	2	Positive	16	Alive
26	71	E	II	N0	M0	II	II	1	2	Positive	14	Dead
27	56	E	II	N1	M0	II	IIIC	3A	2	Positive	15	Dead
28	58	E	II	N0	M0	I	II	3A	1	Negative	5	Dead
29	58	K	II	N0	M0	I	II	3B	1	Negative	31	Alive
30	65	E	II	N0	M0	II	II	1	3	Positive	28	Dead
31	51	E	II	N2	M0	II	IVA	3A	2	Positive	16	Dead
32	64	K	II	N1	M0	II	IIIC	3B	1	Negative	8	Dead
33	69	E	II	N1	M0	II	IIIC	3A	2	Negative	19	Dead
34	59	E	II	N0	M0	III	II	3A	2	Negative	6	Dead
35	57	E	II	N2	M0	III	IVA	3A	2	Negative	11	Dead
36	65	E	II	N0	M0	I	II	3B	1	Negative	40	Dead
37	58	K	II	N0	M0	I	II	3B	1	Negative	57	Alive
38	63	K	III	N1	M0	II	IIIC	3A	1	Negative	60	Dead
39	74	E	II	N1	M0	I	IIIC	3B	1	Negative	30	Dead
40	59	K	II	N0	M0	II	II	3A	2	Positive	53	Alive
41	60	K	II	N1	M0	I	IIIC	3B	2	Negative	24	Dead
42	49	K	I	N0	M0	II	I	3B	1	Negative	18	Dead

**Table 4.** Univariate and multivariate analyses of variables affecting survival in 42 patients undergoing resection for hilar cholangiocarcinoma

	No. of patients	Univariate analysis p	Multivariate analysis Hazard ratio	Multivariate analysis p
Age (median, range), years				
<65	28			
≥65	14	0.25	0.53 (0.07-3.63)	0.5
Gender				
Male	28			
Female	14	0,01	0,18 (0,03-1,10)	0,06
Tumor differentiation				
G1	20			
G2 and G3	22	0,85	4,97(0,5-48,9)	0,1
Proximal resection margin				
Negative	28			
Positive	14	0,64	0,21 (0,02-2,03)	0,17
Preoperative CA19-9. U/mL				
<37	12			
≥37	30	0.02	0.39 (0.05-2.81)	0.35
Lymph node metastasis (AJCC 8th edition)				
Absent	28			
Present	14	0.76	2.64 (1.42-5.28)	0.02
Preoperative bilirubin				
<5	22			
≥5	20	0.01	2.27 (0.4-12.01)	0.33
American Joint Committee on Cancer staging (8 <sup>th</sup> edition)				
Stage 1-2	26			
Stage 3-4	16	0.12	0.18 (0.03- 1.10)	0.07

## DISCUSSION

Surgical resection is the mainstay of treatment for HC. It is a lethal disease, and the 5-year survival rate is very poor. Hepatic resection is widely accepted as an essential part of surgery and provides increased rates of complete resection (4,5). Recent studies have demonstrated that negative resection margins can be achieved by the help of major hepatic resections and are associated with improved survival (11). Status of the ductal margin is the main prognostic factor in resectability, and positive ductal margin is usually considered as a poor prognostic factor (12-14).

Over the last decade, advances in diagnostic imaging, surgical techniques, and perioperative care have resulted in increased curative resection rates. Hemming et al. (12) demonstrated that patients with R1 resection have some

survival advantage compared with patients with unresectable disease. Lee et al. (13) showed that the 5-year survival rate after R1 resection is not significantly lower than that after R0 resection.

Shingu et al. (14) also reported that additional resection in 12 patients yields negative margins in 8, suggesting that additional resection of the proximal bile duct does not contribute to the improvement of survival, and negative margins are obtained in a small number of patients.

Lee et al. (13) and Shingu et al. (14) also noted that the survival of patients achieving R0 resection margin at the first frozen section examination has better results than those achieving R0 resection margin at the second frozen section.

In our study, R0 resection margins were obtained on the first frozen section examination in 18 patients and on the second frozen section examination in 10 patients. There was no significant difference between these two groups ( $p=0.19$ ).

The 1- and 2-year survival rates were not significantly different between the R1 resection group and the R0 resection group.

Lee et al. (13) found that 5 of the 7 patients with negative margins after additional resection experienced tumor recurrences and died of relapsing disease, indicating that additional resection of the duct for positive margin does not lead to improved survival. In our study, although long-term survival was not different between patients with positive proximal surgical margins and patients with negative proximal surgical margins, patients with positive proximal surgical margins commonly suffer from malignant biliary strictures and frequently need multiple percutaneous procedures. Shingu et al. (14) also reported that additional resection of the bile duct does not contribute to any advantage of survival, and negative margins can be obtained in only a small number of patients.

Although a negative proximal bile duct surgical margin has a beneficial impact on prognosis after surgical resection, it is not the only prognostic factor. Even if negative margins cannot be achieved, impaired survival may be avoided with complete resection of all gross disease (15).

The frozen section method is an essential process for hepatobiliary surgeons. It is helpful to confirm the surgical margin status. Okazaki et al. (16) reported the accuracy rate of frozen sections for the bile duct margin of HC as only 57%. Yamaguchi et al. (17) also reported the inaccuracy rate of frozen sections for the bile duct margin as high as 25%. Although previous studies concluded that the reliability of frozen sections is limited, our results indicated that frozen sections and permanent paraffin-embedded sections were consistent.

For univariate analysis, preoperative elevated levels of total bilirubin, male gender, and elevated CA19-9 levels ( $>37$  U/mL) were found as statistically significant predictors of poor overall survival. Recent studies have found a positive correlation between preoperative biliary drainage and improved post-resection liver remnant (18-20). We advocate the drainage of the liver to decrease serum bilirubin to  $<5$  mg/dL to improve the function of the liver remnant. In accordance with previous studies, node me-

tastasis is found as an independent prognostic factor for multivariate analyses (21-23).

Achieving negative proximal surgical margins in the surgical management of HC is often challenging. Our results demonstrate that frozen section examination is convenient for the evaluation of the ductal margin status for malignant or benign process.

The major limitations of the present study are its retrospective design and only patients who had been referred for surgical evaluation were included.

Actual resectability rate would be determined well if all of the HCs were included in the study. The other limitations are the small number of the study group and the poor prognosis of the disease that does not allow to drawing any conclusion about the long-term follow-up. Further large volume prospective studies are required to identify the impact of positive proximal margins on the survival rate.

Survival of patients with HC is poor even after potentially curative resection. If there is no distant metastasis, then surgical resection should be attempted by any means necessary. Primary surgical resection should not be avoided even if a negative surgical margin does not appear to be possible. During surgery, if any evidence of tumor positive margin is detected, then additional resection of the proximal duct is advised if technically possible.

In our study, survival of patients with tumor positive margins is not found to be worse than those with tumor negative margins. Therefore, aggressive surgery based on liver resection involving the caudate lobe may increase the number of patients with cure and improve their survival even if the margin status is positive; however, further detailed and extensive well-designed research with larger study groups is needed.

**Ethics Committee Approval:** The authors declared that the research was conducted according to the principles of the World Medical Association Declaration of Helsinki "Ethical Principles for Medical Research Involving Human Subjects", (amended in October 2013).

**Informed Consent:** Written informed consent was obtained from all the patients who participated in this study.

**Peer-review:** Externally peer-reviewed.

**Author Contributions:** Concept - V.O., I.O., E.B.B.; Design - M.U., V.O., C.B.; Supervision - E.B.B., I.O.; Resource - T.D., I.O., E.B.B.; Materials - V.O., C.B., T.D.; Data Collection and/or Processing - V.O., C.B., T.D.; Analysis and/or Interpretation - V.O., M.U., I.O.; Literature Search - V.O., M.U., T.D.; Writing - V.O., I.O., C.B.; Critical Reviews - E.B.B., I.O., M.U.

**Conflict of Interest:** The authors have no conflict of interest to declare.

**Financial Disclosure:** The authors declared that this study has received no financial support.

## REFERENCES

1. Khan SA, Thomas HC, Davidson BR, Taylor-Robinson SD. Cholangiocarcinoma. *Lancet* 2005; 366: 1303-14. [\[CrossRef\]](#)
2. De Jong MC, Marques H, Clary BM, The impact of portal vein resection on outcomes for hilar cholangiocarcinoma: a multiinstitutional analysis of 305 cases. *Cancer* 2012; 118: 4737-47. [\[CrossRef\]](#)
3. Nagino M, Ebata T, Yokoyama Y Evolution of surgical treatment for perihilar cholangiocarcinoma: a single-center 34-year review of 574 consecutive resections. *Ann Surg* 2013; 258: 129-40. [\[CrossRef\]](#)
4. Kawasaki S, Imamura H, Kobayashi A, et al. Results of surgical resection for patients with hilar bile duct cancer: application of extended hepatectomy after biliary drainage and hemihepatic portal vein embolization. *Ann Surg* 2003; 238: 84-92. [\[CrossRef\]](#)
5. Sano T, Shimada K, Sakamoto Y, et al. One hundred two consecutive hepatobiliary resections for perihilar cholangiocarcinoma with zero mortality. *Ann Surg* 2006; 244: 240-7. [\[CrossRef\]](#)
6. Nishio H, Nagino M, Nimura Y. Surgical management of hilar cholangiocarcinoma: the Nagoya experience. *HPB (Oxford)* 2005; 7: 259-62. [\[CrossRef\]](#)
7. Baton O, Azoulay D, Adam DVR, Castaing D. Major hepatectomy for hilar cholangiocarcinoma type 3 and 4: prognostic factors and longterm outcomes. *J Am Coll Surg* 2007; 204: 250-60. [\[CrossRef\]](#)
8. Konstadoulakis MM, Roayaie S, Gomatos IP, Labow D, Fiel MI, Miller CM, Schwartz ME. Aggressive surgical resection for hilar cholangiocarcinoma: is it justified? Audit of a single center's experience. *Am J Surg* 2008; 196: 160-9. [\[CrossRef\]](#)
9. Endo I, House MG, Klimstra AD, et al. Clinical significance of intraoperative bile duct margin assessment for hilar cholangiocarcinoma. *Ann Surg Oncol* 2008; 15: 2104-14. [\[CrossRef\]](#)
10. Bismuth H, Corlette MB. Intrahepatic cholangioenteric anastomosis in carcinoma of the hilus of the liver. *Surg Gynecol Obstet* 1975; 140: 170-8.
11. Geng Z-m et al. Advances in diagnosis and treatment of hilar cholangiocarcinoma - a review. *Med Sci Monit* 2013; 19: 648-56. [\[CrossRef\]](#)
12. Hemming AW, Reed AI, Fujita S, et al. Surgical management of hilar cholangiocarcinoma. *Ann Surg* 2005; 241: 693-9, discussion 699-702. [\[CrossRef\]](#)
13. Lee J.H, Hwang D.W, Lee S.Y. The proximal margin of resected hilar cholangiocarcinoma: the effect of microscopic positive margin on long-term survival. *The American Surgeon* 2012; 78: 471-7.
14. Shingu Y, Ebata T, Nishio H, et al. Clinical value of additional resection of a margin-positive proximal bile duct in hilar cholangiocarcinoma. *Surgery* 2010; 147: 49-56. [\[CrossRef\]](#)
15. Cannon RM, Brock G, Buell JF. Surgical resection for hilar cholangiocarcinoma: experience improves resectability. *HPB* 2012; 14: 142-9. [\[CrossRef\]](#)
16. Okazaki Y, Horimi T, Kotaka M, Morita S, Takasaki M. Study of the intrahepatic surgical margin of hilar bile duct carcinoma. *Hepato-gastroenterology* 2002; 49: 625-7.
17. Yamaguchi K, Shirahane K, Nakamura M, et al. Frozen section and permanent diagnoses of the bile duct margin in gallbladder and bile duct cancer. *HPB (Oxford)* 2005; 7: 135-8. [\[CrossRef\]](#)
18. Seyama Y, Kubota K, Sano K, et al. Longterm outcome of extended hemihepatectomy for hilar bile duct cancer with no mortality and high survival rate. *Ann Surg* 2003; 238: 73-83. [\[CrossRef\]](#)
19. Nimura Y. Preoperative biliary drainage before resection for cholangiocarcinoma. *HPB (Oxford)* 2008; 10: 130-3. [\[CrossRef\]](#)
20. Takada T. Is preoperative biliary drainage necessary according to evidence-based medicine? *J Hepatobiliary Pancreat Surg* 2001; 8: 58-64. [\[CrossRef\]](#)
21. Jarnagin WR, Fong Y, DeMatteo RP, et al. Staging, resectability, and outcome in 225 patients with hilar cholangiocarcinoma. *Ann Surg* 2001; 234: 507-17, discussion 517-9. [\[CrossRef\]](#)
22. Baton O, Azoulay D, Adam DV, Castaing D. Major hepatectomy for hilar cholangiocarcinoma type 3 and 4: prognostic factors and long term outcomes. *J Am Coll Surg* 2007; 204: 250-60. [\[CrossRef\]](#)
23. Kitagawa Y, Nagino M, Kamiya J, et al. Lymph node metastasis from hilar cholangiocarcinoma: audit of 110 patients who underwent regional and paraaortic node dissection. *Ann Surg* 2001; 233: 385-92. [\[CrossRef\]](#)