

Primary gallbladder melanoma in dysplastic nevus syndrome: Report of case and literature review

Jasmina GLIGORIJEVIC¹, Vesna ZIVKOVIC¹, Biljana DJORDJEVIC¹, Irena DIMOV²

Department of ¹Pathology and ²Immunology, University of Nis, School of Medicine, Yugoslavia

A case of gallbladder malignant melanoma in a 62-year-old woman is reported. The gallbladder, resected for tumor mass seen on ultrasound examination, revealed neoplastic epithelioid cells with dark granules in the cytoplasm. These cells with pigment were positive immunohistochemically for S-100, HMB45 and vimentin. The patient, affected by dysplastic nevus syndrome, had a history of a melanoma in situ in her left upper arm that was excised 11 years ago. This is only the second case reported to date of primary malignant melanoma in dysplastic nevus syndrome.

Key words: Gallbladder, primary malignant melanoma, dysplastic nevus syndrome, immunohistochemistry

Displastik nevus sendromunda primer safra kesesi melanomu: Olgu sunumu ve literatür taraması

Burada safra kesesi malign melanomu olan 62 yaşındaki kadın hasta sunulmuştur. Ultrason tetkikinde saptanan tümöral kitle nedeniyle rezeke edilen safra kesesinde, sitoplazmik koyu granüller içeren epitelioid hücreler saptandı. Bu pigmentli hücreler, immünohistokimyasal olarak S-100, HMB45 ve vimentin için pozitif idi. Hastanın displastik nevus sendromu vardı ve 11 yıl önce sol kolundan in situ melanom eksizyonu öyküsü bulunuyordu. Bu olgu, displastik nevus sendromunda şimdiye dek bildirilmiş ikinci primer malign melanom olgusudur.

Anahtar kelimeler: Safra kesesi, primer malign melanoma, displastik nevus sendromu, immünohistokimya

INTRODUCTION

Gallbladder primary melanoma is an extremely rare entity. Controversy about the existence of this primary entity (1,2) is evident in published descriptions of such cases in the literature. There are 30 cases published to date (2-28).

Metastatic malignant melanoma is more frequent. After the initial opinion that those metastases are rare in the gastrointestinal tract (GIT), there is growing evidence that they account for 15% in the gallbladder (29). Although metastases in the gallbladder are a rare event, malignant melanoma represents 50-60% of them (30-32). The most conflicting area is the histogenesis of this primary entity or its possibility. Ricci and coworkers (28) showed melanocytes, both normal and malignant, in their case of malignant melanoma of the gallbladder.

We present herein a case of malignant melanoma of the gallbladder in dysplastic nevus syndrome.

CASE REPORT

A 62-year-old woman, G.I., was admitted for cholecystectomy on 7 March 2009 in a local hospital. She had a history of symptoms in the form of uneasiness and pain in the epigastrium for two years, and had been treated successfully with antacids. Two weeks before surgical treatment, the symptoms worsened: pain in the right upper quadrant became severe, followed by nausea and vomiting. Gastroscopy was performed on the suspicion of *Helicobacter pylori* infection. Urease test was negative and gastric biopsy revealed gastritis. Abdominal ultrasound disclosed gallbladder with doub-

Address for correspondence: Jasmina GLIGORIJEVIC
Medical Faculty, Department of Pathology,
University of Nis
Yugoslavia
E-mail: prof.jasminagligorijevic@gmail.com

Manuscript received: 25.07.2010 **Accepted:** 23.12.2010

Turk J Gastroenterol 2011; 22 (6): 626-630
doi: 10.4318/tjg.2011.0278

le wall contour and polypoid projection almost totally filling the lumen of the organ (Figure 1). No calculi were demonstrated. At the time of the physical examination, there were no pigmented lesions of the skin. Blood and liver function tests were normal, as well as serum amylase levels. X-rays of the chest and flat plate of the abdomen were negative. An upper GI series revealed no abnormalities. After the repeated episode of a severe pain, the patient was admitted to the surgical department for an open surgery, and cholecystectomy was performed. The attending surgeon described a palpable mass within the gallbladder, which felt attached to the peritoneal aspect of the wall. The liver was felt to be normal, and cystohepatic triangle nodes were not enlarged. The gallbladder and cystic duct lymph node were sent to the pathologist in the laboratory of a local hospital for pathology. They were reported as malignant neop-

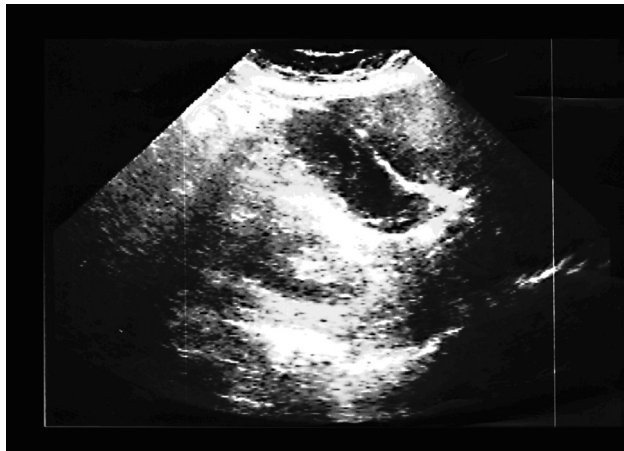

Figure 1. Ultrasound examination outlines a polypoid mass within the gallbladder.

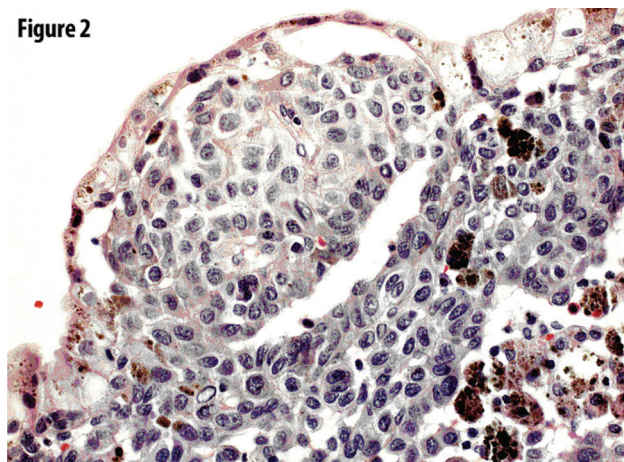


Figure 2. Part of the tumor showing melanin-pigmented cells in small clumps or isolated among epithelial cells, resembling junctional change. Note also pigmented granules superficially in epithelial cells (HMB45 immunostaining x200).

lasm with uncertain histogenesis. The sample was sent to our laboratory for definitive diagnosis.

We received paraffin-embedded gallbladder and tumor tissues. Tissue samples were stained by hematoxylin and eosin (HE), methods for demonstrating melanin and immunohistochemical procedure for vimentin, S-100, HMB-45, and cytokeratin.

Histological Analysis

The polypoid tumor, 2x1x0.5 cm, was composed of solid groups or sheets of plump spindle-shaped cells covered by tall columnar cells in the lamina propria (Figure 2) of the gallbladder. Pigment deposits varied from fine brownish granules in most of the tumor cells to coarser dark brown granules arranged in clumps scattered at random through the main bulk of the tumor (Figure 3). Individual tumor cells were also seen within the columnar epithelium.

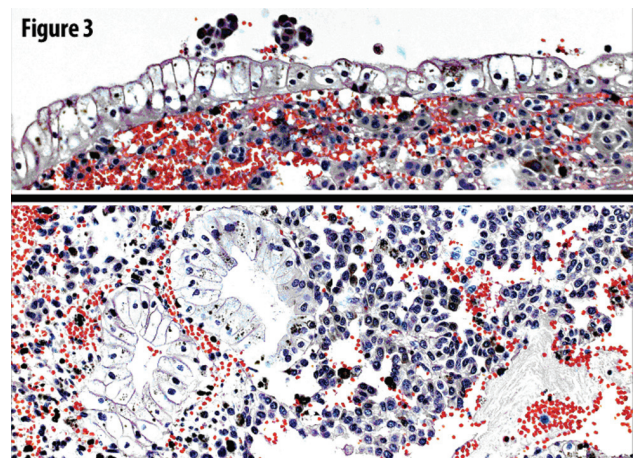


Figure 3. Melanoma cells growing among gallbladder mucosal glands (HE x200).

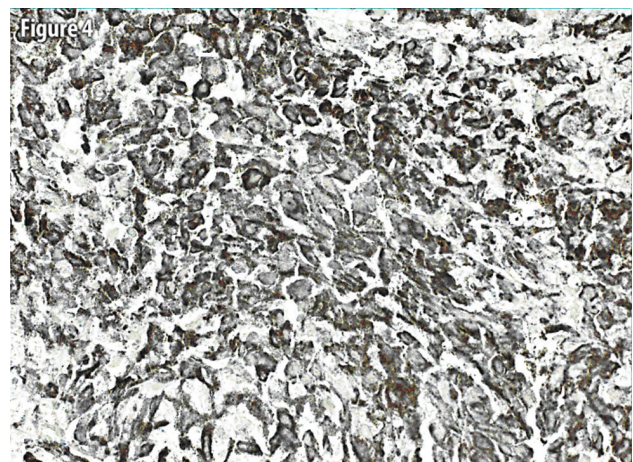


Figure 4. HMB45 immunostaining of the tumor cells x200. Dark pigmented granules of positive immunostain are seen.

Table 1. Gallbladder malignant melanoma reported in the literature

Case	Reference No.	Time of diagnosis	Gender	Age	Tumor size and shape	Metastases at the time of diagnosis	Criteria for considering tumor as primary
1.	Wieting and Hamdi (3)	Necropsy	F	40	Single polypoid mass 2x1.2x1.1 cm	+	No primary tumor elsewhere
2.	Rosenthal (4)	Necropsy	M	48	Polypoid with narrow pedicle 4.5x4x2 cm + 3 satellite lesions	+	No primary tumor elsewhere
3.	Pautler and Gallavan (5)	Necropsy	M	65	Single polypoid 4x3x3 cm	+	Meninges were likely primary
4.	Thayer (6)	Cholecystectomy	F	69	Single, papillary	+	Meninges as a primary site
5.	Walsh (7)	Cholecystectomy	M	45	Single trilobulated 7.5x2.5x1 cm	+	Junctional change
6.	Jones (8)	Necropsy	M	72	Polypoid with pedicle 6.5x3.5x3 cm	+	Gross morphology + no primary tumor elsewhere
7.	Raffensperger (9)	Cholecystectomy	F	46	Polypoid 1.5 cm + separate macular lesion	+	No primary tumor elsewhere
8.	Debiec et al (10)	Cholecystectomy	F	71	Single polypoid size not stated	–	No primary tumor elsewhere
9.	Simmard (11)	Necropsy	F	74	Multiple plaques	–	No primary tumor elsewhere
10.	Simmard (11)	Necropsy	F	71	Multiple small polypoid	+	No primary tumor elsewhere
11.	Peison and Rabin (12)	Cholecystectomy	M	58	Soft, dark tissue over the mucosa	–	No primary tumor elsewhere
12.	Peison and Rabin (12)	Cholecystectomy	M	54	Single polypoid 4x3x0.7 cm	–	Junctional component
13.	Peison and Rabin (12)	Cholecystectomy	M	50	Single polypoid 3x2x1.5 cm	–	No primary tumor elsewhere
14.	SierraCallejas and Warecka (13)	Necropsy	M	44	Two closely located polypoid tu 2x1.5x1.3 cm 2.2x1.4x1 cm	–	No primary tumor elsewhere
15.	Hatae et al. (14)	Cholecystectomy	M	72	Single ill-defined solid, 2x2 cm	–	No primary tumor elsewhere
16.	Carle et al. (15)	Cholecystectomy	F	47	Single polypoid 1.5 cm	+	Junctional component
17.	Anderson et al. (16)	Cholecystectomy	F	45	Two separate polypoid 4 cm each	+	Gross morphology
18.	Borja et al. (17)	Cholecystectomy	M	31	Polypoid, broad based 2 cm+ two separate nodules	+	Gross morphology
19.	Naguib and Aterman (18)	Cholecystectomy	M	25	Irregular papillary, broad based 2.2x2.2x0.7 cm	–	Gross morphology+ junctional changes+ no primary tumor
20.	Seul (19)	Cholecystectomy	M	48	single polypoid, broad based 1.5x1cm	–	Gross morphology+ junctional changes+ no primary tumor
21.	Rudolph (20)	Cholecystectomy	F	51	Single polypoid, broad based 4.5x3 cm	–	Gross morphology+ no primary tumor elsewhere
22.	Verbanck et al. (21)	Cholecystectomy	F	52	Single polypoid 5x4x4 cm	+	Gross morphology+ no primary tumor elsewhere
23.	Dong et al. (22)	Cholecystectomy	M	55	Single polypoid narrow based 5x2.5x2.2 cm	–	No primary tumor elsewhere
24.	Heath and Womack (23)	Cholecystectomy	M	29	Single papillary 2.5 cm	+	Gross morphology+ no primary tumor elsewhere
25.	Guerini et al. (24)	Cholecystectomy	M	73	Single polypoid 1.8 cm	+	Gross morphology+ no primary tumor elsewhere
26.	Habeck (25)	Necropsy	M	57	Single polypoid 4 cm	+	Gross morphology+ no primary tu elsewhere
27.	Hatanaka et al. (26)	Cholecystectomy	M	51	Single polypoid 3.5x2x0.8 cm	+	Gross morphology+ no primary tu elsewhere
28.	Velez et al. (27)	Cholecystectomy	F	62	Single small 3.5x2x0.8 cm	–	Gross morphology+ no primary tu elsewhere
29.	Ricci et al. (28)	Cholecystectomy	F	58	Small dark polypoid	–	No primary tumor elsewhere
30.	Safioleas (2)	Cholecystectomy	F	38	Polypoid mass 1.5x2 cm	–	No primary tumor elsewhere
31.	Present case						

Tu: Tumor.

Immunoperoxidase in formalin-fixed paraffin-embedded tissue disclosed malignant cells positive for vimentin, S-100 and HMB-45 (Figure 4) and negative for cytokeratin, confirming the diagnosis of malignant melanoma. There were no metastases in the lymph node of cystic duct.

After reaching the diagnosis, the patient's pigmented cutaneous lesion on the right upper arm was questioned, as it was not presented in the medical documentation of the patient. This was the first such diagnosis in our laboratory, and it was suspected at first that this could be a secondary deposit of malignant melanoma. The pigmented skin lesion had been operated in 1998 with a diagnosis of dysplastic nevus. After obtaining this knowledge, a broad and detailed investigation of the patient's health was performed. Computed tomography (CT) of the abdomen and pelvis did not disclose secondary deposits. CT of the head and chest as well as bone scan revealed no metastatic disease.

The patient has been without additional therapy or complaints. She is in good condition eight months after the operation.

According to the literature criteria, the presented case is primary melanoma of the gallbladder in dysplastic nevus syndrome.

DISCUSSION

Thirty cases of primary malignant melanoma of the gallbladder have been reported in the literature (Table 1).

Although there are no precise evidences about the origin of cells that differentiate towards malignant melanoma in the gallbladder, nor it is possible to make the diagnosis on the basis of clinical symptomatology, we face the fact that such cases have been published before. The simple frequency is one case every three years from the time Wieiting (3) first described this entity on autopsy in 1907. In the first 50 years, most gallbladder malignant melanomas were diagnosed at autopsy. Advancement in diagnostic procedures, and especially advancement in echo radiography, have made diagnosis possible during the life of the patients. The outcome is uneventful, but there is the example of a 13-year survival (27). Malignant melanoma shows pronounced tropism for metastatic spread in the liver and gallbladder. The presence

of melanocytes in the mucosa (28) represents the theoretical base for this primary entity to occur.

All authors agree that it is almost impossible to differentiate between primary and metastatic malignant melanoma on the basis of histomorphologic characteristics. This can be complicated by additional circumstances: the primary tumor can be small and may preclude clinical identification; spontaneous regression of malignant melanoma can make this distinction impossible. The small number of cases is obviously insufficient for establishing the stable criteria for the diagnosis. We propose that diagnostic criteria have to be divided in two groups as certain and variable criteria. The first group includes: the absence of another primary site of this neoplasm, histomorphologic and immunohistochemical characteristics of the neoplasm, size, polypoid shape, and junctional activity. The variable group consists of presence of metastasis, gallbladder calculi, and age and gender of the patient. All of these criteria for distinguishing primary from secondary malignant melanoma in the gallbladder are weak, especially if we look at them separately. In fact, metastatic melanoma can have polypoid pattern (31), or may be in the form of a single tumor mass (22,32), or can show intraepithelial spread and junctional activity, or can be a single metastatic position (33,35,36). There are recommendations about the obvious presence of certain characteristics (23) for making the diagnosis of this primary entity. According to all characteristics, the presented case is primary malignant melanoma in dysplastic nevus syndrome, and this is the second report of such an entity in the literature. The occurrence of dysplastic nevus years before cholecystectomy potentially favors secondary gallbladder involvement. This precedent is irrelevant because melanomas in situ have a negligible risk of metastases (34); there was a long period separating the two events, and dysplastic nevus syndrome increases the risk of developing primary melanoma (37,38).

In conclusion, we report a case of primary gallbladder melanoma with all characteristics for distinguishing between the primary and metastatic forms. It was not intended to resolve the controversy with this article. We just comment that inability to explain the neoplasm does not preclude its existence.

REFERENCES

- Higgins CM, Strutton GM. Malignant melanoma of the gallbladder-does primary melanoma exist? *Pathology* 1995; 27: 312-4.
- Safioleas M, Agapitos E, Kontzoglou K, et al. Primary melanoma of gallbladder: Does it exist? Report of case and review of literature. *World J Gastroenterol* 2006; 12(26): 4259-61.
- Wieting H, Hamdi G. Über die physiologische und pathologische Melaninpigmentierung und den epithelialen Ursprung der melanoblastome. Ein primäres melanoblastom der Gallenblase. *Beitr Anat Allg Pathol* 1907; 42: 24-84.
- Rosenthal SR. Primary melanocarcinoma of the gallbladder. *Am J Cancer* 1931; 15: 2289-300.
- Pautler EE, Gallavan EM. Primary melanocarcinoma of the gallbladder. *Arch Pathol* 1951; 51: 238-45.
- Thayer KH, Williams OO, Rowe D. Malignant melanoma of the gallbladder. *Ariz Med* 1955; 12: 15-8.
- Walsh TS. Primary melanoma of gallbladder with cervical metastases and fourteen and a half years survival. *Cancer* 1956; 6: 518-22.
- Jones CH. Malignant melanoma of the gallbladder. *J Pathol Bact* 1961; 81: 423-30.
- Raffensperger EC, Branson FW, Triano G. Primary melanoma of the gallbladder. *Am J Dig Dis* 1963; 8: 356-363.
- Debiec H, Kiryłowicz K, Hrba Z. Dwa przypadki czarniaka złośliwego pęcherzka żółciowego. *Przegl Lek* 1966; 6: 643-5.
- Simmard C, George P, Cautlet T, et al. Les mélanomes maligns de la vésicule biliaire. Rapport de deux cas. *J Chir (Paris)* 1966; 92: 51-8.
- Peison B, Rabin L. Malignant melanoma of the gall bladder: report of three cases and review of the literature. *Cancer* 1976; 37: 2448-54.
- Sierra-Callejas JL, Warecka K. Primary malignant melanoma of the gallbladder. *Virchows Arch* 1976; 370: 233-8.
- Hatae Y, Kikuchi M, Segawa M, et al. Malignant melanoma of gallbladder. *Pathol Res Practice* 1978; 163: 281-7.
- Carle G, Lessels AM, Best PV. Malignant melanoma of the gallbladder: a case report. *Cancer* 1981; 48: 2318-22.
- Anderson JB, Hughes RG, Williamson RN. Malignant melanoma of the gallbladder. *Postgrad Med* 1983; 59: 390-1.
- Borja RS, Meyer WR, Cahill JP. Malignant melanoma of gallbladder: report of a case. *Cancer* 1984; 54: 929-31.
- Naguib SE, Aterman K. Presumed primary malignant melanoma of the gallbladder: report of a case and a review of literature. *Am J Dermatopathol* 1984; 6 (Suppl 1): 231-43.
- Seul B, Luchtrath H. Malignes melanomes der Gallenblase. *Chirurg* 1984; 55: 179-81.
- Rudolph A, Bothe J, Bonk U. Malignes melanom der Gallenblase. *Chirurg* 1985; 56: 469-71.
- Verbanck JJ, Rutgeerts LJ, Van Aelst FJ, et al. Primary malignant melanoma of gallbladder, metastatic to the common bile duct. *Gastroenterology* 1986; 91: 214-8.
- Dong XD, De Matos P, Pietro VG, et al. Melanoma of gallbladder; a review of cases seen at Duke University Medical Center. *Cancer* 1999; 85: 32-9.
- Heath DI, Womack C. Primary malignant melanoma of the gallbladder. *J Clin Pathol* 1986; 41: 1073-7.
- Guerini A, Gottardi D, Galassi A, et al. Malignant melanoma of the gallbladder: case report and review of the literature. *Arch Anat Cytol Pathol* 1990; 38: 168-70.
- Habeck JO. Primary malignant melanoma of the gallbladder. Case report and literature review. *Zentralbl Pathol* 1993; 139: 367-71.
- Hatanaka N, Miyata M, Kamiike W, et al. Radical resection of primary malignant melanoma of the gallbladder with multiple metastases: report of a case. *Surg Today* 1993; 23: 1023-6.
- Velez AF, Penetrante RB, Spellman JE, et al. Malignant melanoma of the gallbladder: report of a case and review of the literature. *Am Surg* 1995; 61: 1095-8.
- Ricci R, Maggiano N, Martini M, et al. Primary malignant melanoma in dysplastic nevus syndrome. *Virch Arch* 2001; 438: 159-65.
- Das Gupta T, Brasfield R. Metastatic melanoma: a clinicopathological study. *Cancer* 1964; 17: 1323-39.
- Backman H. Metastasis of malignant melanoma in the gastrointestinal tract. *Geriatrics* 1969; 24: 112-20.
- Mills SE, Cooper PH. Malignant melanoma of the digestive system. *Pathol Annu* 1983; 18: 1-26.
- McFadden M, Krementz ET, McKinnon WN, et al. Metastatic melanoma of the gallbladder. *Cancer* 1979; 44: 1802-8.
- Bedo F, Hoffer L, Bely M, et al. Isolated metastasis in the gallbladder from malignant cutaneous melanoma discovered by ultrasound. *Orv Hetil* 1996; 137: 1427-8.
- Langley RGB, Bailey EM, Sober AJ. Acute cholecystitis from metastatic melanoma to the gall-bladder in patient with a low-risk melanoma. *Br J Dermatol* 1997; 136: 279-82.
- Guida M, Cramarossa A, Gentile A, et al. Metastatic malignant melanoma of the gallbladder: a case report and review of the literature. *Melanoma Res* 2002; 12: 619-25.
- Guery D, Synnestvedt M, Elder DE, et al. Lessons from tumor progression: the invasive radial growth phase of melanoma is common, incapable of metastases and indolent. *J Invest Dermatol* 1993; 100: 342s.
- Langer K, Rappersberger K, Steiner A, et al. The ultrastructure of dysplastic naevi: comparison with superficial spreading melanoma and common naevocellular naevi. *Arch Dermatol Res* 1990; 282: 353-62.
- Rhodes AR, Seki Y, Fitzpatrick TB, et al. Melanosomal alterations in dysplastic melanocytic nevi. *Cancer* 1988; 61: 358-69.