

# Prognostic significance of MUC1, MUC2 and MUC5AC expressions in gastric carcinoma

Mide kanserlerinde MUC1, MUC2 ve MUC5AC ekspresyonunun prognostik önemi

Özgür İLHAN, Ünsal HAN, Binnur ÖNAL, Serkan Yaşar ÇELİK

Department of Pathology and Cytology, Dışkapı Yıldırım Beyazıt Education and Research Hospital, Ankara

**Background/aims:** The aim of this study was to investigate the expressions of some of the Mucus Core Proteins (MUC) - MUC1, MUC2 and MUC5AC - in gastric carcinomas, to assess their prognostic values and their relations with the clinicopathological characteristics. **Methods:** MUC1, MUC2 and MUC5AC expressions were investigated immunohistochemically in 257 patients with gastric carcinomas. **Results:** MUC1 was strongly expressed in normal gastric epithelium; however, the expression rate decreased with the loss of tumor differentiation (92.6% in well differentiated tumors, 83.7% in poorly differentiated tumors), with an increase in the number of metastatic lymph nodes (98.4% in tumors with no metastatic lymph nodes, 67.9% in tumors with lymph node metastasis-pN3), and with the progression in the tumor stage (100% in stage 1 tumors, 75.6% in stage 4 tumors). MUC1 expression was lower in distant metastatic tumors (83.3% in distant metastatic tumors and 90.8% in nonmetastatic tumors). There was no staining with MUC2 in normal gastric epithelium; however, de novo expressions appeared in tumoral tissues. In diffuse gastric carcinomas (mucinous and signet ring cell carcinomas), MUC2 expression was higher (97.5% in diffuse type and 89.4% in intestinal type). All of the mucinous carcinomas were MUC2-positive. The expression rate decreased with an increase in the number of metastatic lymph nodes and with the progression in the TNM stages of the cases. All of the tumors with intestinal metaplasia were MUC2- positive. MUC5AC was strongly expressed in normal gastric epithelium; however, the expression rate decreased with the loss of tumor differentiation, with an increase in the tumor invasion depth, and with an increase in the number of metastatic lymph nodes. MUC5AC expression was higher in intestinal type carcinoma (48.4%) than in the diffuse type (10%). The lowest expression rate was in the diffuse type according to the Borrmann's macroscopic classification. All of these results were statistically significant ( $p < 0.05$ ). **Conclusions:** When each of these three markers is evaluated, in the light of clinical and pathological parameters, MUC1 and MUC5AC may be accepted as significant prognostic parameters and may be useful in showing the progression of the tumors; MUC2 may be used in determining the mucinous carcinomas.

**Key words:** Gastric carcinoma, MUC1, MUC2, MUC5AC, immunohistochemistry, prognosis

**Amaç:** Bu çalışmada mide kanserlerinde MUC1, MUC2 ve MUC5AC ekspresyon oranlarını saptamak, klinikopatolojik değişkenlerle karşılaştırmak ve prognostik önemlerini tartışmak amaçlanmıştır. **Yöntem:** Mide kanseri olarak raporlanan 257 hastaya ait tümörlü parafin bloklara immünohistokimyasal yöntemle (indirek immünperoksidaz yöntemi) MUC1, MUC2 ve MUC5AC antikorları çalışıldı. **Bulgular:** MUC1 normal gastrik epitelde kuvvetle eksprese olurken; tümör diferansiasyonunu kaybettikçe, artan metastatik lenf düğümü sayısı ile ve tümör evresi attıkça ekspresyon oranı azaldığı saptanmıştır. Uzak metastatik tümörlerde MUC 1'in ekspresyonu çok düşüktür. Diffüz tip gastrik kanserlerde MUC2 ekspresyonu yüksek bulunurken müsinöz tip kanserlerin tümü pozitif saptandı. Ekspresyon oranı metastatik lenf düğümü sayısı arttıkça ve TNM evresi ilerledikçe azalmaktadır. MUC5AC normal gastrik epitelde kuvvetle eksprese olurken; tümör diferansiasyonunu kaybettikçe, tümör invazyon derinliği arttıkça ve metastatik lenf düğümü sayısı arttıkça ekspresyonunun azaldığı saptandı. En az ekspresyon oranı Borrmann makroskopik sınıflamasına göre diffüz tipte bulundu. Bu sonuçların hepsi istatistiksel olarak anlamlı idi. **Sonuç:** Sonuç olarak bu bulguların ışığında: MUC 1 ve MUC 5AC önemli prognostik parametre olarak kabul edilebilir ve tümör progresyonunu göstermede kullanılabilir. MUC2 ise müsinöz tip tümörleri belirlemede kullanılabilir.

**Anahtar kelimeler:** Mide kanseri, MUC1, MUC2, MUC5AC, immünohistokimya, prognoz

**Address for correspondence:** Ünsal HAN

SB Ankara Dışkapı Yıldırım Beyazıt Eğitim ve Araştırma Hastanesi, Patoloji&Sitoloji, Ankara, Turkey  
Phone: + 90 312 596 26 91  
E-Mail: unsalhan@yahoo.com

**Manuscript received:** 22.10.2009 **Accepted:** 14.02.2010

doi: 10.4318/tjg.2010.0119

## INTRODUCTION

Mucins are high molecular weight glycoproteins that contain a central polypeptide (apomucin) with numerous attached carbohydrate chains. Their functions are to form a mucous gel covering the surfaces of epithelial tissues in order to lubricate and protect them (1-8). Their genes are clustered on chromosome 11p15.5 (4). In recent studies, 20 different human mucin genes coding apomucins have been identified (MUC 1, 2, 3A, 3B, 4, 5AC, 5B, 6, 7, 8, 9, 11, 12, 13, 15, 16, 17, 18, 19, 20) (1, 9, 10).

MUC1 (episialin) is a membrane-bound mucin, which is expressed in many epithelial tissues like the breast, pancreas, and gastrointestinal, respiratory and urinary systems. It is widely expressed especially in the lactational breast. In addition, it is accepted as a normal gastric mucin, cytoplasmic and lumenally expressed in foveolar cells in the stomach, and chief and parietal cells in corpus glands. MUC1 expression rates were studied in gastric, colonic and pancreatic adenocarcinomas and in breast carcinomas in many researches (1-3, 5-7, 11-20).

MUC2 is the main mucin of the intestinal mucosa and respiratory system, and does not show any staining in normal gastric epithelium; however, *de novo* expressions appear in the areas of intestinal metaplasia (IM) and in malignancies (1-8, 13-20). The expression of MUC2 is very common in mucinous carcinomas of different organs such as breast, colon and prostate (21-23).

MUC5AC, a gastric-type mucin of the cardia and corpus of the stomach, is widely expressed in normal gastric epithelium (3, 4, 6-8, 13-20).

Mucin profiles of tissues, such as synthesis and glycosylation rates, show many changes in carcinomas. These changes, playing a great role in cellular growth and adhesion and also in immune system regulation, affect the invasion and metastatic capacity of the tumor. In many studies, decreases in the expression rates of MUC1 and MUC5AC and *de novo* MUC2 expression in gastric carcinomas have been shown to be correlated with the prognosis (1-8, 13-20).

In this study, we investigated MUC1, MUC2 and MUC5AC expressions and their relations with the clinicopathological characteristics in a large series of gastric carcinomas composed of 257 patients, in order to compile additional information about the prognostic factors in gastric carcinomas.

## MATERIALS AND METHODS

### Patients

Gastrectomy specimens of 257 patients (201 males, 56 females) with gastric carcinomas diagnosed in the Pathology Department of the Ministry of Health Ankara Dışkapı Training and Research Hospital between January 2000 and December 2007 were selected for this study. None of the patients received preoperative chemotherapy or radiation therapy. The data on the age of the patients, tumor location and distant metastasis were obtained by reviewing clinical charts and pathological records. Hematoxylin-eosin slides of the cases were evaluated by two pathologists retrospectively. Histological classifications, according to the World Health Organization (WHO) (24) and Lauren (25) and macroscopic classification, according to the Borrmann's classification (26), were done. In addition, differentiation of adenocarcinoma and IM in nontumoral epithelium, invasion depth of tumor (pT), lymph node metastasis (pN), perinodal invasion in metastatic lymph nodes, and perineural and angiovascular invasions were evaluated separately for each case. Tumor staging was done using Tumor Node Metastasis (TNM) system according to the American Joint Committee on Cancer (AJCC) (27). The clinicopathological parameters evaluated are shown in Table 1.

### Immunohistochemistry

Hematoxylin-eosin slides of all the tumor tissues were evaluated, and for each case, the best paraffin block, having the least necrosis and hemorrhage and the highest tumor content, was chosen in order to prevent artefact staining. These formalin-fixed, paraffin-embedded blocks were sliced in 2.5 µm thicknesses, deparaffinized and rehydrated. Microwave pre-treatment using 0.01M sodium citrate buffer was only employed to the slides of MUC5AC. All the slides were incubated with 3% hydrogen-peroxide in phosphate buffered saline (PBS) for 20 minutes (min) at room temperature in order to block endogenous peroxidase activity. Immunoperoxidase staining was performed using the streptavidin-biotin peroxidase method. The tissue sections of each case were incubated with MUC1 (Neomarkers, RB-9222-P, 1:100), MUC2 (Neomarkers, MS-1037-P, 1:100) and MUC5AC (Neomarkers, MS-145-P, 1:100) primary antibodies at room temperature for 1 hour (h). 3-amino-9-ethylcarbazole (AEC) was used as the chromogene and hematoxylin as the counterstain. The positive

**Table 1.** The clinicopathological parameters evaluated in this study

Parameter	Number of the cases (n)	Percentage of the cases (%)	Parameter	Number of the cases (n)	Percentage of the cases (%)
<b>Age*</b>			<b>pT Stage</b>		
<50	54	21.0	pT1	7	2.7
≥50	203	79.0	pT2	16	6.2
<b>Tumor Location*</b>			pT3	225	87.6
Proximal	34	13.2	pT4	9	3.5
Distal	208	81.0	<b>pN Stage</b>		
Diffuse	15	5.8	pN0	63	24.5
<b>Borrmann's Classification</b>			pN1	111	43.2
Polypoid (Type 1)	8	3.1	pN2	55	21.4
Fungiform (Type 2)	5	1.9	pN3	28	10.9
Ulcerated (Type 3)	218	84.8	<b>Perinodal Invasion*</b>		
Diffuse (Type 4)	26	10.2	-	89	34.6
<b>Lauren's Classification</b>			+	168	65.4
Intestinal-type	217	84.4	<b>Distant Metastasis</b>		
Diffuse-type	40	15.6	M0	251	97.7
<b>Tumor Type</b>			M1	6	2.3
Adenocarcinoma	217	84.4	<b>TNM Stage</b>		
Mucinous	21	8.2	Stage 1	19	7.4
Signet ring cell	19	7.4	Stage 2	49	19.1
<b>Differentiation of Adenocarcinoma</b>			Stage 3	148	57.6
Well	27	10.5	Stage 4	41	15.9
Moderate	98	38.1	<b>Perineural Invasion*</b>		
Poor	92	35.8	-	38	14.8
<b>Intestinal Metaplasia*</b>			+	219	85.2
-	108	42.0	<b>Angiovascular Invasion*</b>		
+	149	58.0	-	75	29.2
			+	182	70.8

\*Parameter was not statistically significant with three of the mucins.

controls were breast carcinoma tissue for MUC1, normal colonic mucosa for MUC2 and normal gastric mucosa for MUC5AC. PBS was used instead of primary antibody as negative control.

The 'expression rate', the extent of staining for each MUC, was scored according to the number of cytoplasmic and luminal stained carcinoma cells in 100 tumor cells. Less than 5% positive cells was accepted as negative, while ≥5% positive cells was accepted as positive.

Scoring: 0 (negative): <5% positive cells;  
1+ (positive): 5-50% positive cells;  
2+ (positive): >50% positive cells.

### Statistical Analysis

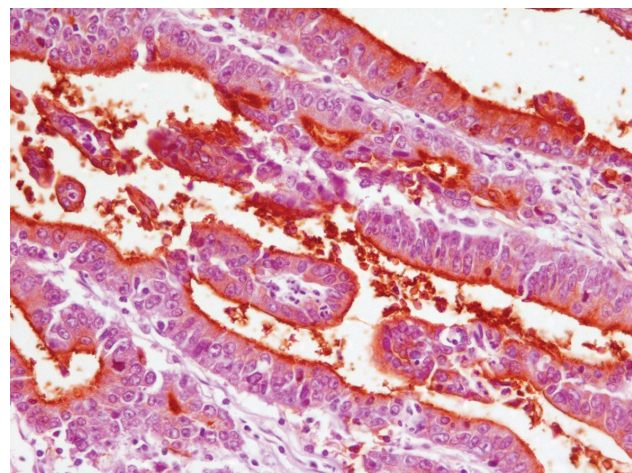
Statistical analysis was performed using chi-square and Fisher's exact tests. *P* values less than 0.05 were considered to be statistically significant.

## RESULTS

### MUC1 Expression

MUC1 showed strong cytoplasmic and luminal expression in normal gastric epithelium. The correlations between MUC1 expression rate and the clinicopathological parameters that were statisti-

cally significant are shown in Table 2. The expression rate decreased with the loss of tumor differentiation. The staining was positive in 92.6% of well differentiated tumors (Figure 1), but only positive in 83.7% of poorly differentiated tumors. The expression rate was 98.4% in the cases with no metastatic lymph nodes; however, it decreased in metastatic pN3 cases (67.9%). Distant metastatic cases showed a tendency to lose the expression (the



**Figure 1.** MUC1 expression in well differentiated adenocarcinoma (x 200).



**Table 2.** Correlations between MUC1 expression rates and the clinicopathological parameters that are statistically significant

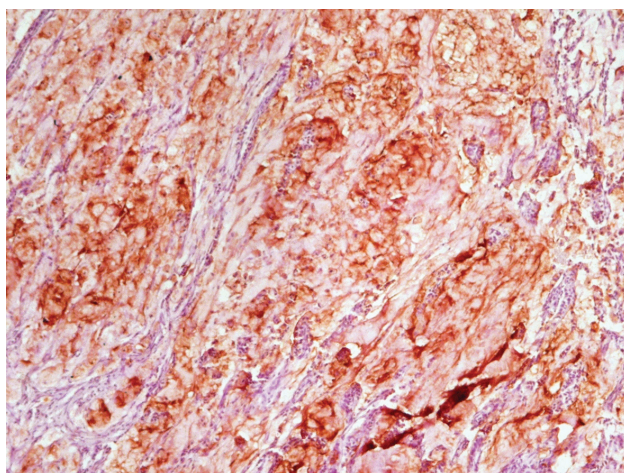
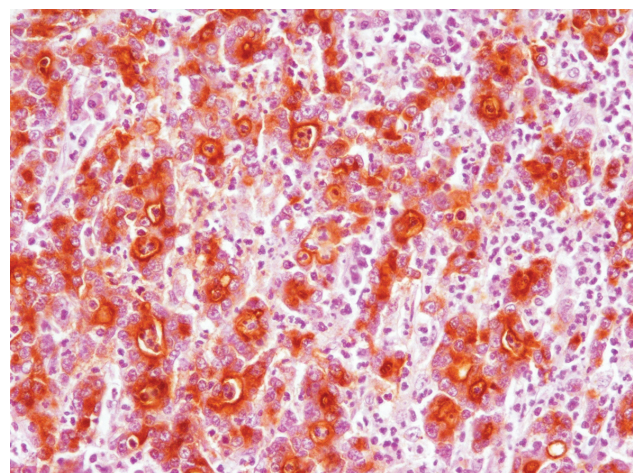
	Score 0	MUC1 Score 1	Score 2	Total n (%)
<b>Differentiation of Adenocarcinoma</b> (p=0.006) ( $\chi^2=14.488$ )				
Well	2 (7.4)	7 (25.9)	18 (66.7)	27 (100)
Moderate	4 (4.1)	33 (33.7)	61 (62.2)	98 (100)
Poor	15 (16.3)	39 (42.4)	38 (41.3)	92 (100)
Total n (%)	21 (9.7)	79 (36.4)	117 (53.9)	217 (100)
<b>Metastatic Lymph Node Stage (pN)</b> (p=0.001) ( $\chi^2=22.284$ )				
pN0	1 (1.6)	24 (38.1)	38 (60.3)	63 (100)
pN1	10 (9.0)	43 (38.7)	58 (52.3)	111 (100)
pN2	4 (7.3)	22 (40.0)	29 (52.7)	55 (100)
pN3	9 (32.1)	8 (28.6)	11 (39.3)	28 (100)
Total n (%)	24 (9.3)	97 (37.8)	136 (52.9)	257 (100)
<b>Distant Metastasis (M)</b> (p=0.03) ( $\chi^2=6.987$ )				
M0	23 (9.2)	92 (36.6)	136 (54.2)	251 (100)
M1	1 (16.7)	5 (83.3)	0 (0.0)	6 (100)
Total n (%)	24 (9.4)	97 (37.7)	136 (52.9)	257 (100)
<b>TNM Stage</b> (p=0.003) ( $\chi^2=19.990$ )				
1	0 (0.0)	6 (31.6)	13 (68.4)	19 (100)
2	3 (6.1)	20 (40.8)	26 (53.2)	49 (100)
3	11 (7.4)	52 (35.1)	85 (57.5)	148 (100)
4	10 (24.4)	19 (46.3)	12 (29.3)	41 (100)
Total n (%)	24 (9.4)	97 (37.7)	136 (52.9)	257 (100)

loss was 16.7% in M1 cases and 9.2% in M0 cases). The expression rate was lower in the cases with advanced TNM stages (100% in stage 1 tumors, 75.6% in stage 4 tumors). However, no statistically significant correlation was seen between MUC1 expression and the age, tumor location and type, Lauren's and Borrmann's classifications, depth of tumor invasion (pT), and the presence of perinodal, angiovascular, perineural invasions and IM in nontumoral epithelium (p>0.05) (Table 1).

### MUC2 Expression

There was no MUC2 expression in normal gastric epithelium; however, *de novo* expressions appeared

in tumoral tissues as shown in Table 3. MUC2 expression rate was higher in diffuse type (mucinous and signet ring cell) gastric carcinomas (Figures 2, 3) (97.5% in diffuse type and 89.4% in intestinal type). There was diffuse and strong (100%, 2+) staining in all of the mucinous carcinomas. However, 2+ expression was observed in 73.7% of signet ring cell carcinomas and 44.7% of adenocarcinomas. All of the well differentiated but only 77.2% of the poorly differentiated adenocarcinomas were MUC2-positive. The expression rate decreased with an increase in the number of metastatic lymph nodes and the progression in the TNM stage. In TNM stage 1 cases, the positivity

**Figure 2.** MUC2 expression in mucinous carcinoma (x 100).**Figure 3.** MUC2 expression in signet ring cell carcinoma (x 200).

**Table 3.** Correlation between MUC2 expression rates and the clinicopathological parameters that are statistically significant

	Score 0	MUC2 Score 1	Total n (%) Score 2	
<b>Lauren's Classification</b> (p=0.000) ( $N^2=24.776$ )				
Intestinal-type	23 (10.6)	97 (44.7)	97 (44.7)	217 (100)
Diffuse-type	1 (2.5)	4 (10.0)	35 (87.5)	40 (100)
Total n (%)	24 (9.3)	101 (39.3)	132 (51.4)	257 (100)
<b>Tumor Type</b> (p=0.000) ( $N^2=27.532$ )				
Adenocarcinoma	23 (10.6)	97 (44.7)	97 (44.7)	217 (100)
Mucinous	0 (0.0)	0 (0.0)	21 (100.0)	21 (100)
Signet ring cell	1 (5.3)	4 (21.1)	14 (73.7)	19 (100)
Total n (%)	24 (9.3)	101 (39.3)	132 (51.4)	257 (100)
<b>Differentiation of Adenocarcinoma</b> (p=0.000) ( $N^2=58.448$ )				
Well	0 (0.0)	1 (3.7)	26 (96.3)	27 (100)
Moderate	2 (2.1)	61 (62.2)	35 (35.7)	98 (100)
Poor	21 (22.8)	35 (38.0)	36 (39.2)	92 (100)
Total n (%)	23 (10.6)	97 (44.7)	97 (44.7)	217 (100)
<b>Metastatic Lymph Node Stage (pN)</b> (p=0.000) ( $N^2=32.306$ )				
pN0	2 (3.2)	20 (31.7)	41 (65.1)	63 (100)
pN1	7 (6.3)	45 (40.5)	59 (53.2)	111 (100)
pN2	5 (9.1)	26 (47.3)	24 (43.6)	55 (100)
pN3	10 (35.7)	10 (35.7)	8 (28.6)	28 (100)
Total n (%)	24 (9.3)	101 (39.3)	132 (51.4)	257 (100)
<b>TNM Stage</b> (p=0.000) ( $N^2=30.170$ )				
1	1 (5.3)	7 (36.8)	11 (57.9)	19 (100)
2	2 (4.1)	13(26.5)	34 (69.4)	49 (100)
3	9 (6.1)	65 (43.9)	74 (50.0)	148 (100)
4	12 (29.3)	16 (39.0)	13 (31.7)	41(100)
Total n (%)	24 (9.3)	101 (39.3)	132 (51.4)	257 (100)

was 94.7%, while it was 70.7% in stage 4 cases. There was no statistically significant relation with the rest of the clinicopathologic parameters ( $p>0.05$ ) (Table 1). All of the tumors with IM showed MUC2 expression; however, this was not statistically significant ( $p>0.05$ ).

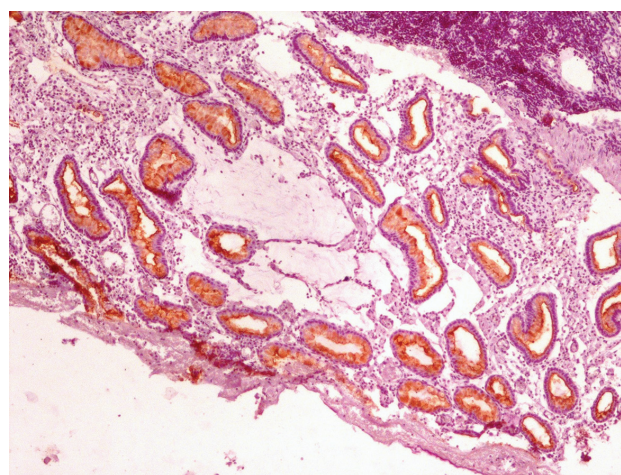
### MUC5AC Expression

MUC5AC was strongly expressed in normal gastric epithelium. The correlation between MUC5AC expression rate and the clinicopathological parameters is shown in Table 4. According to Lauren's classification, intestinal-type carcinomas showed higher (48.4%) expression rate than the diffuse-type (10%). Most of the mucinous (90.5%) and signet ring cell (89.4%) carcinomas were MUC5AC-negative (Figure 4). The expression rate in well differentiated tumors was 92.6%, while it was 13% in poorly differentiated tumors. There was no loss of MUC5AC expression in pT1 tumors, but 66.7% of the pT4 tumors were negative. This correlation was true also with the metastatic lymph node stage, with the negativity rates of 39.7% in pN0 cases and 89.3% in pN4 cases. According to the TNM stage, stage 4 cases showed higher (82.9%) loss of MUC5AC expression than stage 1 cases (31.6%). The lowest expression rate was in the diffuse type according to the Borrmann's classification. There

was no statistically significant correlation with the rest of the parameters ( $p>0.05$ ) (Table 1).

### DISCUSSION

Gastric carcinoma is one of the most frequent carcinomas. Although the incidence rate has shown a declining trend in recent years, the mortality is still quite high (28, 29). The prognosis of gastric carcinoma depends mostly on the histopathological grade and the stage. However, they are not al-



**Figure 4.** MUC5AC negativity in mucinous carcinoma (x 100).

**Table 4.** Correlation between MUC5AC expression rates and the clinicopathological parameters that are statistically significant

	Score 0	MUC5AC Score 1	Score 2	Total n (%)
<b>Lauren's Classification</b> (p=0.000) ( $\chi^2=20.391$ )				
Intestinal-type	112 (51.6)	73 (33.6)	32 (14.8)	217 (100)
Diffuse-type	36 (90.0)	3 (7.5)	1 (2.5)	40 (100)
Total n (%)	148 (57.6)	76 (29.6)	33 (12.8)	257 (100)
<b>Tumor Type</b> (p=0.000) ( $\chi^2=20.670$ )				
Adenocarcinoma	112 (51.6)	73 (33.6)	32 (14.8)	217 (100)
Mucinous	19 (90.5)	2 (9.5)	0 (0.0)	21 (100)
Signet ring cell	17 (89.4)	1 (5.3)	1 (5.3)	19 (100)
Total n (%)	148 (57.6)	76 (29.6)	33 (12.8)	257 (100)
<b>Differentiation of Adenocarcinoma</b> (p=0.000) ( $\chi^2=184.386$ )				
Well	2 (7.4)	2 (7.4)	23 (85.2)	27 (100)
Moderate	31 (31.6)	58 (59.2)	9 (9.2)	98 (100)
Poor	80 (87.0)	12 (13.0)	0 (0.0)	92 (100)
Total n (%)	113 (52.0)	72 (33.2)	32 (14.8)	217 (100)
<b>Tumor Invasion Depth (pT)</b> (p=0.003) ( $\chi^2=19.653$ )				
pT1	0 (0.0)	3 (42.9)	4 (57.1)	7 (100)
pT2	7 (43.8)	5 (31.2)	4 (25.0)	16 (100)
pT3	135 (60.0)	65 (28.9)	25 (11.1)	225 (100)
pT4	6 (66.7)	3 (33.3)	0 (0.0)	9 (100)
Total n (%)	148 (57.6)	76 (29.6)	33 (12.8)	257 (100)
<b>Metastatic Lymph Node Stage (pN)</b> (p=0.000) ( $\chi^2=32.901$ )				
pN0	25 (39.7)	20 (31.7)	18 (28.6)	63 (100)
pN1	61 (55.0)	37 (33.3)	13 (11.7)	111 (100)
pN2	37 (67.3)	16 (29.1)	2 (3.6)	55 (100)
pN3	25 (89.3)	3 (10.7)	0 (0.0)	28 (100)
Total n (%)	148 (57.6)	76 (29.6)	33 (12.8)	257 (100)
<b>TNM Stage</b> (p=0.000) ( $\chi^2=33.418$ )				
1	6 (31.6)	7 (36.8)	6 (31.6)	19 (100)
2	21 (42.8)	14 (28.6)	14 (28.6)	49 (100)
3	87 (58.8)	48 (32.4)	13 (8.8)	148 (100)
4	34 (82.9)	7 (17.1)	0 (0.0)	41 (100)
Total n (%)	148 (57.6)	76 (29.6)	33 (12.8)	257 (100)
<b>Borrmann's Classification</b> (p=0.024) ( $\chi^2=14.567$ )				
Polypoid	4 (50.0)	3 (37.5)	1 (12.5)	8 (100)
Fungiform	1 (20.0)	1 (20.0)	3 (60.0)	5 (100)
Ulcerated	123 (56.4)	68 (31.2)	27 (12.4)	218 (100)
Diffuse	20 (76.9)	4 (15.4)	2 (7.7)	26 (100)
Total n (%)	148 (57.6)	76 (29.6)	33 (12.8)	257 (100)

ways enough to predict the probability of relapse, metastasis and the overall survival (29, 30). Therefore, new prognostic factors are needed and have been detected in many researches, like mucin profiles of the tumors (1-23).

In this study, the correlation between MUC1, MUC2 and MUC5AC expression rates and the clinicopathological features were analyzed in a series of 257 gastric carcinomas. We demonstrated that MUC1, which is a gastric mucin, showed higher expression rates in intestinal type adenocarcinomas, especially in well- and moderately differentiated types, in agreement with Akyürek *et al.* (2) and Barresi *et al.* (1). The higher expression of MUC1 in well differentiated adenocarcinomas is meaningful in showing gastric differentiation, since MUC1 is a main mucin of normal gastric muco-

sa. In addition, we found that loss of MUC1 expression rate increased with the progress in metastatic lymph node stage (pN), distant metastasis and the TNM stage. All of the TNM stage 1 cases were MUC1-positive, while only 75.6% of the stage 4 cases showed positivity. These results may suggest that the deviation in the normal mucin content of gastric mucosa composed of MUC1 is related with the poorer differentiation, increased metastatic capacity and advanced stage (2, 5).

MUC2 was not expressed in normal gastric mucosa as it is an intestinal type mucin. However, *de novo* expressions appeared in tumors. MUC2 showed significantly higher expression rate in diffuse type carcinomas, especially in mucinous carcinomas, in agreement with Barresi *et al.* (1), Zhang *et al.* (3) and Leteurtre *et al.* (4), but in contrast with



Baldus et al. (5) and Akyürek et al. (2). Baldus et al. (5) reported that MUC2 expression was more frequent in intestinal type adenocarcinomas (tubular and papillary) than the diffuse type (signet ring cell) carcinomas. Akyürek et al. (2) found no significant difference in MUC2 expression between intestinal and diffuse type carcinomas. However, in our study, all of the mucinous carcinomas showed wide and strong MUC2 positivity. This relationship between MUC2 expression and mucinous carcinoma has been previously reported in other organs such as colon, breast, pancreas, ovary, and pseudomyxoma peritonei (21-23). Furthermore, all of the well differentiated intestinal type adenocarcinomas with IM were positive (13). This expression showed a decrease with the loss of differentiation; however, this was not statistically significant ( $p>0.05$ ). In addition, less expression was seen in cases with higher metastatic lymph node stage (pN) and TNM stage. Although these results seem to be conflicting, they may demonstrate that as MUC2 is an intestinal type mucin, its higher expression rates in diffuse types (mucinous and signet ring cell) gastric carcinomas may suggest intestinalization as an alternative pathogenesis to *de novo* expression (2, 31), and thus MUC2 may be a good marker for mucinous carcinomas (1, 3, 4).

Since MUC5AC is a gastric mucin, it was expressed widely in normal gastric mucosa, and loss of expression appeared in tumors, especially in diffuse type (mucinous and signet ring cell) carcinomas compared to the intestinal type. This was similar to Zhang's (3) results, as Zhang et al. found that

the lowest expression rate was in mucinous carcinoma, and the expression rate decreased with the loss of differentiation. However, Leteurtre et al. (4) demonstrated that there was no significant difference between intestinal and diffuse types of carcinomas and between well/moderately differentiated carcinomas and poorly/undifferentiated carcinomas. They also declared that there was no relation with the pT, pN and TNM stages of the cases (4). In addition, in our study, the expression rate of MUC5AC decreased with the loss of tumor differentiation, with the increase in tumor invasion depth and the number of metastatic lymph nodes, and consequently, with the progress in TNM stage. Moreover, the expression rate decreased significantly with the progress in macroscopic Borrmann's classification. The lowest expression rate was seen in diffuse macroscopic type, which has the worst prognosis. These results suggest that MUC5AC, which is a gastric mucin, loses its expression in progressive cases (3). Thus, it can be suggested that the expression of MUC5AC in gastric carcinoma may be a good indicator for prognosis.

In conclusion, mucin expression in gastric carcinoma is fairly complex. However, we conclude that MUC1 and MUC5AC expression rates might be good prognostic parameters in gastric carcinoma, and MUC2 might be a good marker for mucinous carcinoma. When each of these three markers is evaluated in the light of clinical and pathological parameters, all of them may be useful as significant prognostic parameters in showing the progression of the tumors.

## REFERENCES

1. Barresi V, Vitarelli E, Grosso M, et al. Relationship between immunoexpression of mucin peptide cores MUC1 and MUC2 and Lauren's histologic subtypes of gastric carcinomas. *Eur J Histochem* 2006; 50: 301-10.
2. Akyürek N, Akyol G, Dursun A, et al. Expression of MUC1 and MUC2 mucins in gastric carcinomas: their relationship with clinicopathologic parameters and prognosis. *Pathol Res Pract* 2002; 198: 665-74.
3. Zhang HK, Zhang QM, Zhao TH, Li YY, Yi YF. Expression of mucins and E-cadherin in gastric carcinoma and their clinical significance. *World J Gastroenterol* 2004; 10: 3044-7.
4. Leteurtre E, Zerimech F, Piessen G, et al. Relationships between mucinous gastric carcinoma, MUC2 expression and survival. *W J Gastroenterol* 2006; 12: 3324-31.
5. Baldus SE, Zirbel TK, Engel S, et al. Correlation of the immunohistochemical reactivity of mucin cores MUC1 and MUC2 with histopathological subtype and prognosis of gastric carcinomas. *Int J Cancer* 1998; 79: 133-8.
6. Pinto-de-Sousa J, David L, Reis CA, et al. Mucins MUC1, MUC2, MUC5AC and MUC6 expression in the evaluation and differentiation and clinico-biological behaviour of gastric carcinoma. *Virchows Arch* 2002; 440: 304-10.
7. Lee HS, Lee HK, Kim HS, et al. MUC1, MUC2, MUC5AC and MUC6 expressions in gastric carcinomas: their roles as prognostic indicators. *Cancer* 2001; 92: 1427-34.
8. Reis CA, David L, Carvalho F, et al. Immunohistochemical study of the expression of MUC6 mucin and co-expression of the other secreted mucins (MUC5AC and MUC2) in human gastric carcinomas. *J Histochem Cytochem* 2000; 48: 377-88.
9. Chen Y, Zhao YH, Kalaslavadi TB, et al. Genome-wide search and identification of a novel gel-forming mucin MUC19 in glandular tissue. *Am J Respir Cell Mol Biol* 2004; 30: 155-65.
10. Higuchi T, Orita T, Nakanishi S, et al. Molecular cloning, genomic structure and expression analysis of MUC20, a novel mucin protein, up-regulated in injured kidney. *J Biol Chem* 2004; 279: 1968-79.

11. Lightenberg MJ, Kruijshaar L, Buijs F, et al. Cell associated episialin is a complex containing two proteins derived from a common precursor. *J Biol Chem* 1992; 267: 6171-7.
12. Lightenberg MJ, Vos HL, Gennisen AM, Hilken J. Episialin, a carcinoma associated mucin, is generated by a polymorphic gene encoding splice variants with alternative amino termini. *J Biol Chem* 1990; 265: 5573-8.
13. Reis CA, David L, Correa P, et al. Intestinal metaplasia of human stomach displays distinct patterns of mucin (MUC1, MUC2, MUC5AC and MUC6) expression. *Cancer Res* 1999; 59: 1003-7.
14. Zotter S, Hagemen PC, Lossnitzer A, et al. Tissue and tumor distribution of human polymorphic epithelial mucin. *Cancer Rev* 1998; 11/12: 55-101.
15. Gendler SJ, Lancaster CA, Taylor-Papadimitriou J, et al. Molecular cloning and expression of human tumor associated polymorphic epithelial mucin. *J Biol Chem* 1990; 265: 15286-93.
16. Seregini E, Botti C, Massaron S, et al. Structure, function and gene expression of epithelial mucins. *Tumori* 1997; 83: 625-32.
17. Ho SB, Niehans GA, Lyftogt C, et al. Heterogeneity of mucin expression in normal and neoplastic tissues. *Cancer Res* 1993; 53: 641-51.
18. Ho SB, Shekels LL, Toribara NW, et al. Mucin gene expression in normal, preneoplastic and neoplastic human gastric epithelium. *Cancer Res* 1995; 55: 2681-90.
19. Gurbuz Y, Kahlke V, Kloppel G. How do gastric carcinoma classification systems relate to mucin expression patterns? An immunohistochemical analysis in a series of advanced gastric carcinomas. *Virchows Arch* 2002; 440: 505-11.
20. Wakatsuki K, Yamada Y, Narikiyo M, et al. Clinicopathological and prognostic significance of mucin phenotype in gastric cancer. *J Surg Oncol* 2008; 98: 124-9.
21. Hanski C, Hofmeier M, Schmitt-Graff A, et al. Overexpression or ectopic expression of MUC2 is the common property of mucinous carcinomas of the colon, pancreas, breast and the ovary. *J Pathol* 1997; 182: 385-91.
22. Park ET, Gum JR, Kakar S, et al. Aberrant expression of SOX2 upregulates MUC5AC gastric foveolar mucin in mucinous cancers of the colorectum and related lesions. *Int J Cancer* 2008; 122: 1253-60.
23. O'Connell JT, Hacker CM, Barsky SH. MUC2 is a molecular marker for pseudomyxoma peritonei. *Mod Pathol* 2002; 15: 958-72.
24. Hamilton S, Aaltonen LA. Tumours of the stomach in World Health Organization Classification of Tumours of the Digestive System. Lyon: IARCH Press, 2000; Chapter 3; 37-66.
25. Lauren P. The two histological main types of gastric carcinoma: diffuse and so-called intestinal type carcinoma. *Acta Pathol Microbiol Scand* 1965; 64: 31-49.
26. Borrmann R. Geschwülste des Magens und Duodenums. In: Henske F, Lubasch O, eds. *Handbuch der Speziellen Pathologischen Anatomie und Histologie*. Berlin: Julius Springer, 1926.
27. Grene FL. Stomach. In: American Joint Committee on Cancer-AJCC Cancer Staging Manual. 6th ed. New York: Springer, 2002.
28. Fenoglio-Preiser C, Carneiro F, Correa P, et al. WHO histological classification of gastric tumour. In: Hamilton SR, Aaltonen LA, eds. *Tumours of the Stomach in World Health Organization Classification of Tumours. Pathology and Genetics of Tumours of the Digestive System*. Lyon: IARCH Press, 2000; Chapter 3; 37-66.
29. Kelley JR, Duggan JM. Gastric cancer epidemiology and risk factors. *J Clin Epidemiol* 2003; 56: 1-9.
30. Allgayer H, Heiss MM, Schildberg FW. Prognostic factors in gastric cancer. *Br J Surg* 1997; 84: 1651-64.
31. Yamachika T, Inada K, Fujimitsu Y, et al. Intestinalisation of gastric signet ring cell carcinomas with progression. *Virchows Arch* 1997; 431: 103-10.